wjert, 2021, Vol. 7, Issue 2, 135-146. *Review Article* ISSN 2454-695X

World Journal of Engineering Research and Technology

WJERT

www.wjert.org

Impact Factor Value: 5.924

AUTOMATIC SEGMENTATION OF LUMBAR SPINE L1-L5 FOR DETECTION OF OSTEOPOROSIS: REVIEW

Kavita Avinash Patil*[1], K. V. Mahendra Prashanth[2] and Dr. A. Ramalingaiah[3]

*[1]Research Scholar, Dept. of Electronics & Communication Engineering, SJBIT, Faculty, EPCET, Affiliated to VTU, Bangalore, India.

[2]Professor, Dept. of Electronics and Communication Engg SJBIT, Affiliated to VTU Bangalore India.

[3]M.S (Ortho) Orthopedic Doctor.

Article Received on 29/01/2021 **Article Revised on 19/02/2021** **Article Accepted on 09/03/2021**

***Corresponding Author**
Kavita Avinash Patil
Research Scholar, Dept. of Electronics & Communication Engineering, SJBIT, Faculty, EPCET, Affiliated to VTU, Bangalore, India.

ABSTRACT

Osteoporosis is a pathological-disease that erodes the density and quality of bone which increases the risk of fractures and life menacing impediments. It approximately affects larger than 200-million people world-wide which is common in aging-women. The review is on automatically localizing and detection of lumbar-vertebrae using segmentation technique, which is challenging in medical-field. The elementary challenge connected with the above-declared mission is of the recurring structure of vertebral, restraint infield-view, the existence of pathology in the spine (surgical- implant), and reduction of contrast in imaging-modality of aimed structure. So, the dynamic method is adapted that is a Deep learning model used to predict a fully-automatic approach for identification and location of individual lumbar-vertebrae based on appropriate information of image with better dice-coefficient and accuracy. Even a statistical Multi vertebral method is chosen for localizing vertebrae and by iterating the Expectation-Maximization mode is used for registration of statistical Multi vertebral scheme to find the edge-points of an image to attain reliable and fast segmentation of the vertebral-bodies.

KEYWORDS: Osteoporosis, lumbar vertebrae, Automatic, Segmentation, Deep learning.

I. INTRODUCTION

Osteoporosis is a progressive bone disease that mainly affects post-menopausal women. It is expected that one in three women and above 50 has a fracture which is related to Osteoporosis. It indicates that diminishes in normal bone density because of loss in calcium as well as collagen. A loss in bone-density and quality leads to more porous as well as fragile which increases the risk of bone fracture. Osteoporosis is a menacing to44 million people in Americans and other countries which is mainly misdiagnosed and is not controlled medically.[1] In the human body, commonly the fracture occurs due to Osteoporosis at the spine, wrist, and hip. Particularly the often the concern is on hip and vertebral (spinal) fractures and the estimate of osteoporotic-fracture case world-wide as shown in Figure 1. Fracture in vertebra which results in a severe outcome which includes intense back-pain, height–loss, and deformities (Dowager's Hump). The normal and osteoporotic vertebral bone as shown in Figure 2.

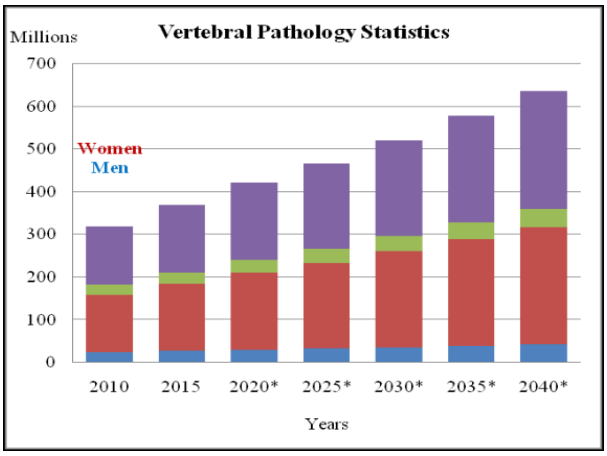

Figure 1: Estimated osteoporotic fracture cases worldwide.

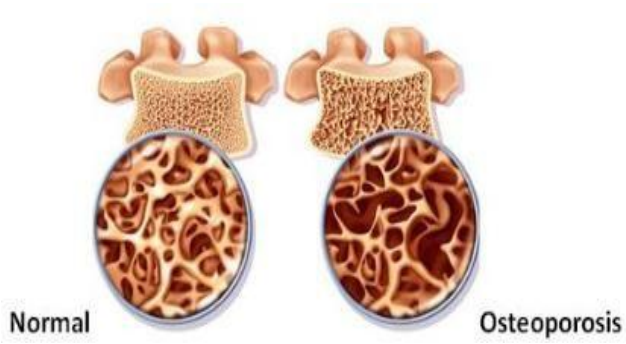

Figure 2: Normal and Osteoporotic Vertebra.

The lower part of the spine which is lumbar vertebrae bear the abdominal cavity and sustains the whole force throughout the normal activity as shown in Figure 3. When compared to

other regions, lumbar-vertebra is larger as well as heavier (denser) than vertebral bodies. Osteoporosis which gives rise to fractures commonly occurs in the vertebrae and the distribution of vertebral-body fractures by location in the spine as shown in Figure 2.The fracture which relates to Osteoporosis is more likely to occur in the vertebrae beginning of the mid-thoracic region. The upper body weight as well as physical pressure bears by vertebrae.[3] The vertebral-body, the block of bone with box type shape consists of an elliptical-block of trabecular (cancellous),[2] bone enclosed by a thin-shell of cortical-bone. At the upper and lower end of an inter-vertebral disc and the ligament of Anterior-Posterior of lateral view are connected d by vertebral-bodies which form a flexible-column shown in Figure 4. and this design gives a light-weight structure that occupies a small amount of materials for construction.

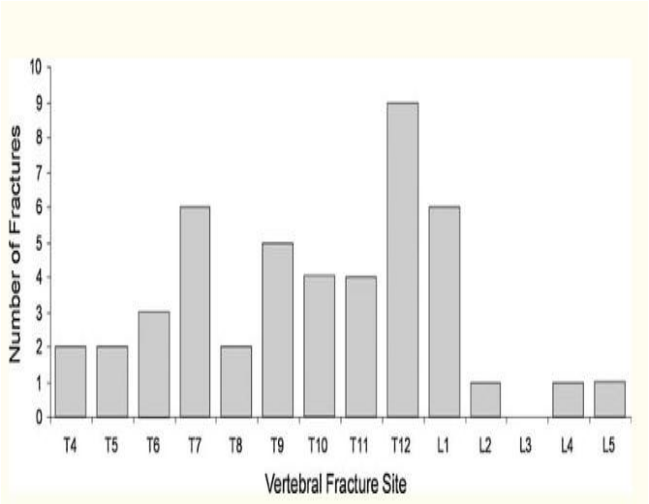

Figure 3: Distribution of vertebral body fractures by location in the spine.

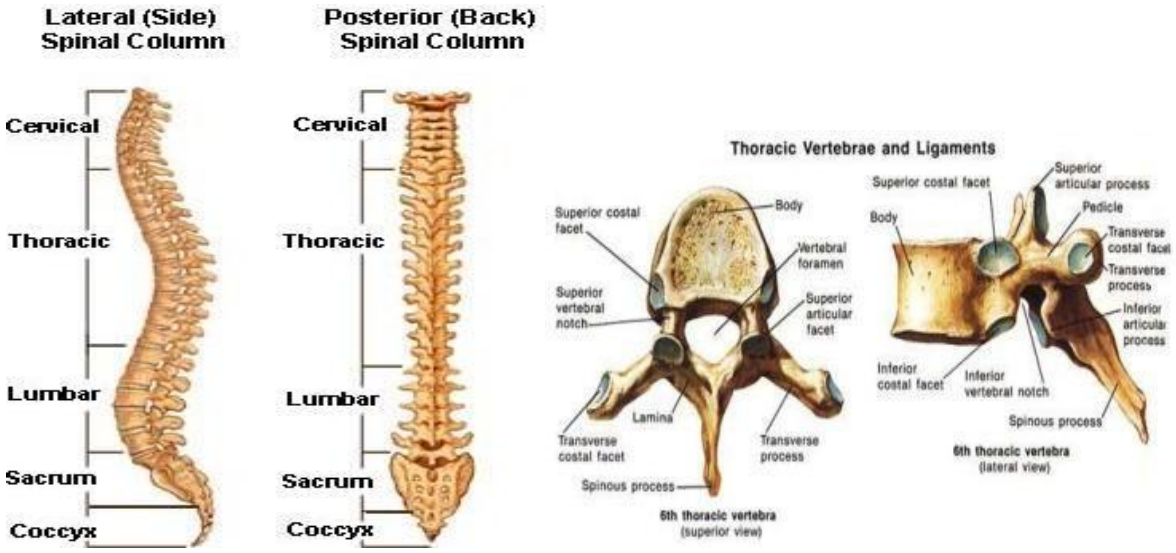

Figure 4: Anatomy of a human vertebra.

Trabecular (cancellous bone-inner, spongy type) normally situated at the end of Long bones which is within the vertebral bodies i.e.in spinal column where it fills up the internal vertebral-space and has a multifaceted 3D architecture.[4] As age increases, the structure of trabecular varies which leads to Osteoporosis. With significant decrease in aging, the trabecular-number as well as bone-vol. (bone- volume) fraction. The trabecular bone-quality in the vertebral body plays a significant

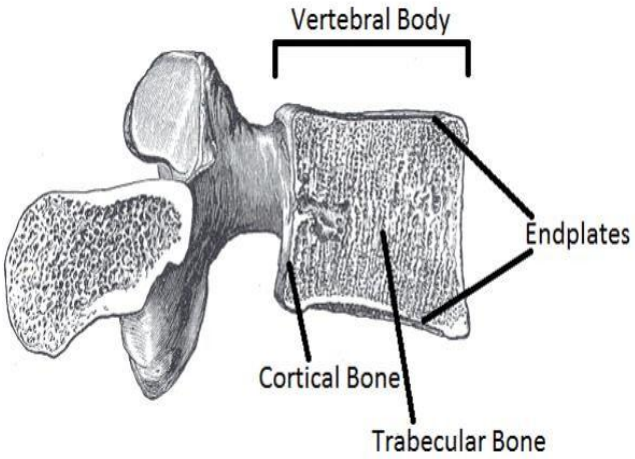

Figure 5: Median section of the vertebra.

Role in performing entire spine. Cortical (Compact bone-dense, outer shell of vertebra),[5] is outer surface of the bone which forms a protective-layer around an internal cavity. It has an 80% of skeletal-mass which is very important to body structure and weight–bearing since it has higher resistance for bending as well as torsion. Thickness of cortical is not specific for sex and it decreases with aging. The vertebrae thickness of cortical varies from 180 to600 m as well as mean-thickness is 380µm.The vertebral trabecular and cortical bone is as shown in Figure 5.

In Segmentation we need to diagnose only the body part (Lumbar vertebrae L1-L5) which is affected by diseases as shown in Figure 6. The labelling and separation,[6] of lumbar vertebral image i.e. L1-L5 as shown in Figure 7. In the vertebral body, the boundary is acquired to find the six-point on posterior, anterior, and counterpart, and at this step recognition of lumbar-vertebral, classifying, and splitting up because of similar texture are taken-off from image i.e. spinal-column. The vertebral body of the Lumbar is detected as well as labelled and at the end, thresholding is done to remove the remaining part which are not in the range of detection and this process continues until all the lumbar- vertebrae i.e. L1-L5 are segregated.



Figure 6: Segmentation of lumbar vertebrae

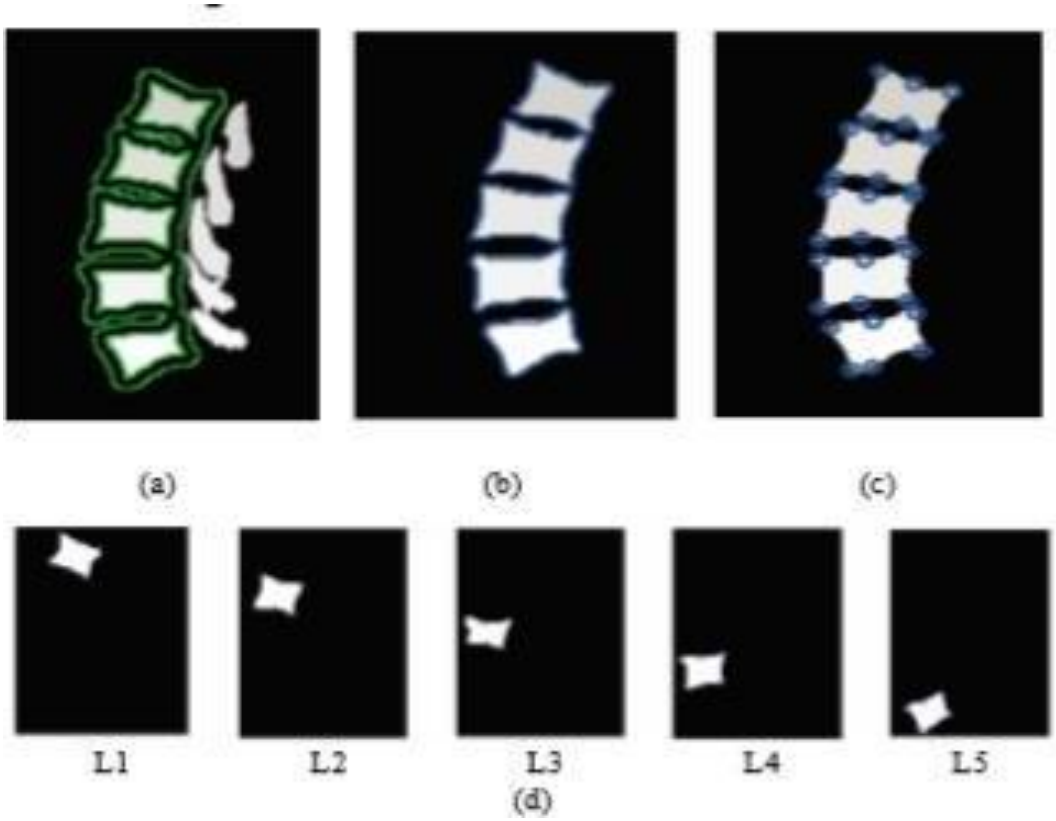

Figure 7: Separating lumbar vertebral, labelling and set six points on body boundary.

In a deep neural network, one of the finest models to detect Osteoporosis is CNN (Convolutional neural network) with good accuracy, sensitivity, and specificity. The input is fed to CNN in the form of images. Numerous layers of,[7] CNN i.e. pooling and Convolutional stages will aid in extracting multifaceted details of images with very few parameters, therefore it is very easy to train. CNN model is used to segment the lumbar

vertebrae from MR-images with high dice score. DNN can achieve a good result when compared with other advanced segmentation process, but it needs huge number of data for training to attain better accuracy.

II. LITERATURE SURVEY

The indication of Osteoporosis is Vertebral fractures (VF). Fractures occur when a bony-block or vertebral body in the spine collapses which leads to severe pain, deforming, and height loss is known as vertebral compression fractures (VCFs) that are painful in nature. The CAD (Computer-Aided Diagnosis) system helps in labelling, detection, and Lumbar Vertebral Body (LVB) segmentation and classification of individual VB - normal, malignant, and benign VCFs. Subsequent to early Pre-processing, Morphological, angular features and shapes are utilized in the labelling, detection, and segmentation step. The Statistical Texture features and numerous shapes are extracted from the segmentation of VB [8] and given to the classifier at the end. Segmentation and classification outcomes are compared with ground–truth manual segmentation of Lumbar Vertebral Body (LVB) as well as decision labels of fractures given by specialists. The Dice similarity coefficient (DSC) is a popular-metric for evaluation of the accuracy of automatic or semi-automatic segmentation methods by comparison of results to the ground truth.

The fully automatic detection of Osteoporosis in LDCT (Low-Dose-Chest-Computed Tomography) Scan achieved for Annual Lung-Cancer screening and Deep learning (DL) built BMD measure method was progressed. Use of QCT[9] a standard reference the performance was evaluated. A better correlation was performed at each and every Vertebral-Level (T12-L2) involving performance as a developed-system and BMD measurement of QCT. The system detected automatically osteoporosis and BMDLOW with a higher value of specificity, accuracy, and sensitivity in scanning LDCT as shown in Table-1. In real-fact, the implementations of Artificial Neural-Networks (ANNs),[10] have been ample assortment and transpire an optimistic field in the medical industry. ANN is significant in spine research and can be used as a tool in clinical practice (spine field) which enhances in terms of efficiency, diagnosis of disease, prognosis, data standardization, the generalization of models, and prediction of results.

Accurate automatic segmentation of vertebrae in CT-Images (computed tomography) is significant for the quantitative study of vertebrae associated disease however it remains challenging because major changes occur in spine- anatomy along with patients. The deep

learning method to automate the segmentation of CT-vertebra termed as a Patch- Based Deep Belief Network's (PaDBNs).[11] The model- PaDBN selects automatically features from Image-Patches and determine the dissimilarity among classes as well as scrutinize performance. From CT images, the ROI (region of interest) is acquired. Un-Supervised reduction of feature, Contrastive-Divergence algorithm is pertained to initializing the weights and the weights are improved via layers in Supervised fine-tuning process. The selective learning- feature is used as input for classification to achieve the probability of vertebrae. The results of the PaDBN –model can minimize the cost and generate better performance in segmenting the vertebra in stipulations of accuracy in contrast with other methods.

Diagnosis of bone-diseases like Osteoporosis, Osteopenia, and Scoliosis, segmentation of vertebral pose is a significant feature. The X-ray images which are low in radiation regularly used to diagnose these diseases,[12] it is done to minimize the dose of radiation risk on the patient which leads to lower accuracy in the detection of the vertebral pose. So, here automation of vertebral-pose segmentation depends on the geometric approach utilizing ellipsoidal-wave on the X-Ray image (human spine). The study depends on two major steps i.e. in the first step pre-processing takes place on gamma-correction where image adjustment is used to enhance the spine region. In the 2nd step which is segmentation approach where the level setting, estimation of edge, and analysis of ellipse are the collective method to trace the vertebral-pose spot. The outcome of these steps can find the position of an individual vertebral pose with accuracy as shown in the table 1. The study was to examine the possible use of clinically given spine-label notation accumulated in the solitary organization image collection as training-data for DL-based on pipelines labelling and detection,[13] of vertebral. The Cervical and lumbar magnetic resonance Imaging (MRI-images) along with spine-labels annotations were recognized and exported from the archived images. Splitting the two separate pipelines are fixed and training was done for cervical and lumbar cases correspondingly, by using the identical arrangement through CNN (Convolutional Neural Networks) for detecting and for labelling the vertebrae by using Parts-based Graphical-Models. The failure of labelling of S1 was not detected and vertebrae were missed which was not seen on the image. All these outcomes that are clinically annotated on the image-data show that 1-image archives adequate for training the DL –based pipelining with respect to the accuracy of detection as well as labelling of MR-images that depict the spine. These DL methods aid radiologists in terms of accurate labelling and make their work easier.

The fracture which occurs in lumbar-vertebrae differs in types and causes which leads to morbid disease that is Osteoporosis. The most common fracture is a Lumbar- wedge compression fracture where the vertebral part is compressed severely which forms a wedge-shape, produces a pain, major pressure on roots of nerve and spine. The segmentation method contains 5 major stages in the direction of the CAD system: In stage-1the location of inter - vertebral discs, stage-2 is Vertebral skeleton location, the stage-3 is Segmenting the each and every vertebra, stage-4 detecting the vertebrae centroid line and in stage-5 detecting the vertebrae main boundary-point. The outcome of segmentation provides average-error (1.5mm varied with Hausdorff distance-metric),[14] on 50 experimental CT cases (lumbar vertebrae-250). An automatic wedge-compression fracture (diagnosis - 15 cases i.e. 7 have a compression fracture of vertebral) with accuracy as shown in the table 1.

In (MR) Magnetic Resonance multi-slice images, the method initiated automatically vertebra labelling, localization, and segmentation. From image-voxels, cubic (intensity-based) features are extracted. The deep learning method is used for the recognition and localization of vertebrae. The localized-points are processed through thresholding (local) in the area of the vertebral detected column. On the localized-vertebrae,[15] the statistically Multi Vertebrae representation is initialized. The iteration of Expectation-Maximization the method is applied to the vertebral body to align the edges and achieve the segmentation for the lumbar vertebral body and the study is assessed by 9-volumetric MR-images of the spine. The outcome exhibit 100% identification of vertebra and surface error mean lesser than 2.8mm for 3-dimensional segmentation. Calculation time is below 3 min per high- resolution volumetric-image.

Magnetic Resonance images is a challenging task for segmenting the vertebral structure since the contrast is poor among bone-surface and adjacent soft tissue. Here a semiautomatic method is used for vertebral body segmentation in multi-slice MR images. To attain fast and definitive segmentation the technique extracts the benefit of co-relation among pose and shape of unlike vertebrae of a similar patient by utilizing the statistical multiple-vertebrae pose+ shape form. The intensity-correction method minimizes the intensities of homogenous in MR images of the spine and for smoothening images a three-dimensional the an- isotropic diffusing filter is used. The edges are extracted from a smaller area of the pre-processed images. Consequently, the iterative Expectation-Maximization.[16] method register uses the statistical-multiple vertebrae extracts the edge-points to attain fast and definitive segmentation for the lumbar- vertebral body. By application of the volumetric MR-image of

the spine (9-patients), the method assesses speed and accuracy. To diagnose the fracture (vertebra wedge- compression) from CT-images, a fully automatic CAD system is used. The localization, labelling and segmentation of vertebrae is used for diagnosing individual vertebra. To achieve segmentation and labelling by means of co-ordinate system which contains - Active-Shape Modelling as well as Gradient Vector-Flow.[17] (GVF-Snake) Active-Contours and set of clinically tested feature that differentiate the fractured-vertebra, these feature are fed to machine learning algorithms which includes unsupervised learning i.e. K-Means and supervised-learning i.e. Neural Network. The validation was done on a set of 50 CT cases with accuracy as shown in table 1.

The Compression fracture of vertebral with a half- way slump of the vertebral body is referred to as (VCF) Vertebral Compression Fracture, where changes occur in types and result in a condition of trauma that is osteoporosis. The occurrence of a medical fault and necessary to have the knowledge to diagnose Osteoporosis disease, researchers thought of using the Intuitive diagnostic technique by representing the information of radiologists by means of machine-learning algorithms. On the Vertebral body, the location, anomaly, and height are resolved by radiologists. In automatic the diagnostic method, the Morphometric features.[18] and the measurement of 3-parts of the vertebral body to diagnose VCF and severe abnormalities in location by segmenting and detecting edges of vertebral. The classification was done by KNN and SVM with better accuracy, sensitivity, and specificity for diagnosing VCF as shown in the table. Due to several causes, vertebral compression fractures frequently go unknown. If it is undetected which leads to establishing osteoporosis. The fully automatic method is used to detect Vertebral-Compression Fractures (VCF).[19] Deep and reinforcement learning used for three-dimensional localization of lumbar and thoracic spine-region. Around the coronal center, the localized region is divided into the two-dimensional sagittal slice. Every slice is split into patches on that trained Convolutional Neural Network –CNN is used to detect compression-fracture.

Table-1: Segmentation results for each lumbar VB computed for different metrics.

Method	Imaging Sequence	Accuracy (%)	Sensitivity (%)	Specificity (%)	Dice Similarity Coefficient (%)
Shape and texture features[8]	L1-L5	95.34	96.97	96.04	94.27
Deep learning model[9]	upper part VBs (T1–T10) to lower part VBs (T11–L2)	97.5	90.37	98.08	86.6
Patch-based deep belief networks (PaDBNs) Model [11]	(T1–T12) and (L1–L5)	93.3	91.1	93.4	86.1
Segmentation Approach(edge assessment, level setting method and ellipse examination) [12]	T12 and L1-L4	79.02	92.54	84.40	-
CNN[13]	T1-weighted	99.6	99.7	99	-
Segmentation method[localization of Discs, skeleton localization of Vertebral, Individual segmentation of Vertebra, Vertebrae centroid and major boundary points of Vertebrae][14]	L1-L5	97.33	91.667	98.413	-
Segmentation method:- Active-Shape Modeling +Gradient Vector-Flow (GVF-Snake) Active-Contours [17]	L1-L5	98	87.5	99.1	-
Morphometric features and segmentation method[18]	L1-L5	86.6	91.4	85	-
CNN[19]	Vertebral fracture	80	79.87	80.73	86

CONCLUSION

The age associated loss of bone and resulting Osteoporosis is an extensive in elderly-population is complex and multifarious, relating to a progressionist bone-loss in quantity as well as quality. During life-time 80-90% suffers from lower back-pain problem which is caused by imperfection in vertebrae, discs or soft-tissues. So, the effectual designing of Computer-Aided method for diagnosis of spine as well as treatment needs a technique for automatic detection and localization of vertebra. The fully-automatic segmentation technique

will be advantage for diagnosing the pathological disease i.e. spine. These techniques must be accurate, robust, reliability and fast so that it will be accepted in clinical trials. To up-shot the classification as well as segmentation, the larger-dataset is required which could be useful for training deep learning model to automate the selection of best features strategy that can be anticipated as the area under discussion for future work.

ACKNOWLEDGEMENT

This work was supported by Dr. A Ramalingaiah M.S (ortho)Orthopedic Doctor, Bangalore. No.271 Abhilasha Orthopaedic Hospital 5th Block 100ft Rd Banashankari 3rd Stage Bangalore - 560085, Bangalore.

REFERENCE

1. https://www.imaginis.com/osteotporosis/introduction-what-is- osteoporosis.
2. https://www.umms.org/ummc/health-services/orthopedics/servicesspine/patient-guides/anatomy-function.
3. https://www.physio-pedia.com/Lumbar_Vertebrae.
4. Luo, Yong, Li Yang, and Maocai Tian, "Application of biomedical- grade titanium alloys in trabecular bone and artificial joints, "Biomaterials and Medical Tribology, Woodhead Publishing, 2013; 181-216.
5. https://www.spine-health.com/glossary/cortical bone#:~:text=This%20type%20of% 20 bone %20also,bone%20disease%20such%20as%20osteoporosis.
6. Yousefi, Hamid, et al., "Lumbar Spine Vertebral Compression Fracture Case Diagnosis Using Machine Learning Methods on CT images,", 2019 4th International Conference on Pattern Recognition and Image Analysis (IPRIA) IEEE, 2019.
7. Areeckal, Anu Shaju, and Michel Kocher, "Current and emerging diagnostic imaging-based techniques for assessment of osteoporosis and fracture risk," IEEE reviews in biomedical engineering, 2018; 12: 254-268.
8. Arpitha, Adela, and Lalitha Rangarajan, "Computational techniques to segment and classify lumbar compression fractures,", La radiologia medica, 2020; 1-10.
9. Pan, Yaling, et al., "Automatic opportunistic osteoporosis screening using low-dose chest computed tomography scans obtained for lung cancer screening,", European Radiology, 2020; 1-10.
10. Azimi, Parisa, et al., "A Review on the Use of Artificial Intelligence in Spinal Diseases,", Asian Spine Journal, Apr 24, 2020.

11. Furqan Qadri, Syed, et al., "Automatic deep feature learning via patch-based deep belief network for vertebrae segmentation in CT images, Applied Sciences, 2019; 9(1): 69.
12. Boonyai, Jakapong, Suwanna Rasmequan, and Pusit Kulkasem, "Automated vertebral pose segmentation based on level set method and bone geometric analysis,", 2018 International Workshop on Advanced Image Technology (IWAIT), IEEE, Jan 7, 2018; 1-4.
13. Forsberg, Daniel, Erik Sjöblom, and Jeffrey L. Sunshine, "Detection and labeling of vertebrae in MR images using deep learning with clinical annotations as training data,", Journal of digital imaging, 2017; 30(4): 406-412.
14. Ghosh, Subarna, et al., "Automatic lumbar vertebra segmentation from clinical CT for wedge compression fracture diagnosis," Medical Imaging 2011: Computer-Aided Diagnosis, International Society for Optics and Photonics, 2011; 7963: 796303.
15. Suzani, Amin, et al., "Deep learning for automatic localization, identification, and segmentation of vertebral bodies in volumetric MR images," Medical Imaging 2015: Image-Guided Procedures, Robotic Interventions, and Modeling. International Society for Optics and Photonics, 2015; 9415: 941514.
16. Suzani, Amin, et al., "Semi-automatic segmentation of vertebral bodies in volumetric MR images using a statistical shape+ pose model," Medical Imaging 2014: Image-Guided Procedures, Robotic Interventions, and Modeling, International Society for Optics and Photonics, 2014; 9036: 90360P.
17. Al-Helo, Samah, et al., "Compression fracture diagnosis in lumbar: a clinical CAD system," International journal of computer assisted radiology and surgery, 2013; 8(3): 461-469.
18. Yousefi, Hamid, et al., "Lumbar Spine Vertebral Compression Fracture Case Diagnosis Using Machine Learning Methods on CT images," 2019 4th International Conference on Pattern Recognition and Image Analysis (IPRIA), IEEE, Mar 6 2019; 179-184.
19. Iyer, Sankaran, et al., "A Novel Approach to Vertebral Compression Fracture Detection Using Imitation Learning and Patch Based Convolutional Neural Network,", 2020- IEEE 17th International Symposium on Biomedical Imaging (ISBI), IEEE, 2020; 726-730.