



MULTI-MODEL VERSATILE THRESHOLD VECTOR ZONE (VTVZ) VESSEL BLOCKAGE SEGMENTATION TECHNIQUE FOR DETECT THE BLOCKAGE IN CORONARY HEART IMAGES

P. Rajesh Kumar*¹ and K. Murugesan²

¹Faculty of Electronics and Communication Engineering, Tagore Institute of Engineering and Technology, Salem, India.

²Professor, Department of Electronics and Communication Engineering, SMK Fomra Institute of Technology, Chennai, India.

Article Received on 06/03/2018

Article Revised on 27/03/2018

Article Accepted on 17/04/2018

***Corresponding Author**

P. Rajesh Kumar

Faculty of Electronics and
Communication
Engineering, Tagore
Institute of Engineering and
Technology, Salem, India.

ABSTRACT

Coronary heart issue has been one of the critical dangers to human health. Coronary angiography is prepared as the best quality level for the appraisal of coronary heart disease. Be that as it may, once in a while the images are difficult to visually comprehend due to the intersection and covering of vessels in the angiogram. Also due to the low balance of the image with the setting and the little blood vessels,

the blurred and fuzzy background of coronary heart image, another blood vessel segmentation strategy utilizing Versatile Threshold Vector Zone (VTVZ) morphology is introduced in this work. Firstly angiogram image is preprocessed utilizing an Adaptive temporal filter which improves the differentiation of a picture. At that point, a close morphological task is being used for vessel segmentation. In the wake of thresholding, the blood vessels of a coronary angiogram are removed. In this work, an adaptive temporal filter has been connected to enter pictures for noise removal took after by versatile threshold vector zone segmentation procedure utilizing enlargement morphology for segmentation of vessel blockage identification. At that point, the blood vessel segmentation process incorporates numerical morphological opening, linearization and noise extraction. The proposed strategy demonstrates the specificity of 99.75%, a sensitivity of 99.98% and an Accuracy of 99.99%.

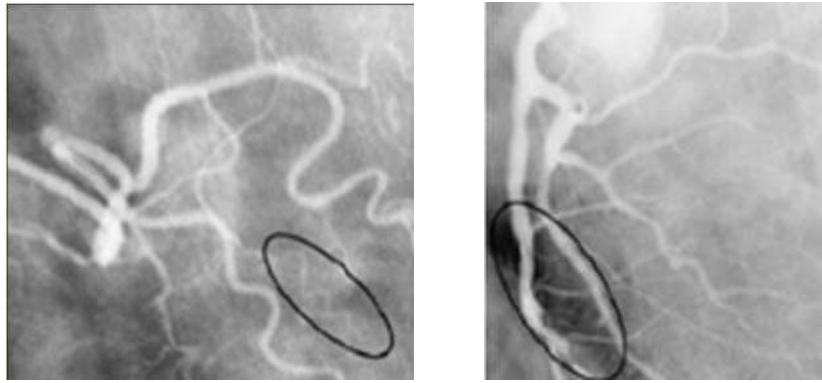It clarifies that the proposed design is fit for identify the vessel blockage region from coronary heart pictures and its capability to help the cardiologists in the clinical practice.

KEYWORDS: Angiogram, coronary, morphology, vessel, VTVZ, IPB.

1. INTRODUCTION

Correct appraisal, particularly accurate perception and evaluation of blood vessels reflected in X-ray angiograms or angiography pictures, assumes a considerable part of various clinical strategies. For different restorative demonstrative undertakings, it is essential to quantify the vessel width, reflectivity, tortuosity, and abnormal stretching. For instance, identifying the event of vessels of a specific width may uncover the indications of stenosis. Reviewing of stenosis is of significance to analyze the seriousness of vascular ailment and to decide the treatment therapy. Besides, arranging and performing neurosurgical methodology requires a correct understanding of blood vessels and their branches, which display extreme changeability. In arranging, they give data on where the blood is drawn and depleted, to separate between the sustaining and transgressing vessel. Indeed, even as transgressing vessels should be saved, the bolstering ones are shut explicitly through the conduit in interventional neuroradiology, for example, the cerebrum arteriovenous deformity treatment. Amid surgery, the vessels serve to give points of interest and rules to the injury.

So, exactness in the route and limitation of clinical techniques is dictated by how minute and unpretentious the vascular data. Despite the fact that it is feasible for medicinal specialists to outline vessels, a manual depiction of the vasculature winds up repetitive or even impossible when the quantity of vessels in an image is extensive or when countless is obtained. Along these lines, the advancement of programmed and exact vessel-tree recreation from angiograms is very desirable. However, it has turned out to be a testing assignment. The critical truth is that vessels can't be described consistently.



a) Low-contrast vessels.

b) Non-uniform illumination.

Fig. 1: Angiography images with typical hindrances.

Thick vessels have more difference to noise proportions when compared with little-limited ones, because of the solid nearness of blood and complexity specialists in the vessels in Figure 1a. Non-uniform brightening, as appeared in Figure 1b, is one of the major sources of angiography image degradation and is also a hindrance for accurate reconstruction, because it is likely to make an individual vessel break into several segments. In this work partitioned the image processing techniques utilized as a part of coronary angiography into two principle classifications: (1) vessel improvement (2) vessel segmentation. These classes are additionally isolated into subcategories. As indicated by the modern programmed PC helped methods are still a long way from giving an exact precise spatial representation of the vessel tree.

In the remaining part of the work, Section II describes the research background. Section III familiarizes our proposed vessel blockage detection method, and Section IV organizes the simulation results of the proposed system. In chapter V presents conclusion and paths to future work.

2. LITERATURE SURVEY

There is a lot of literature available for the techniques, proposed for vessel extraction from coronary angiogram images. Coronary Artery Disease (CAD) is a standout amongst the fatal ailment for human beings,^[1] which has been identified as one of the real reasons for death overall.^[2] In blood vessels, stenosis happens because of plaque gathering in the internal dividers of the courses. Consequently, these vessels turn out to be thin after a particular period.^[3,4] To analyze CAD, medicinal experts perform X-ray angiography as a "best quality level" since this strategy utilizes quick and astounding imaging.^[5,7] Nonetheless, the primary

disadvantage of X-ray angiography is that 3D structures are covered in the anticipated 2D images.^[8,11] This 3D to 2D transformation brings about the loss of angiographic images. This misfortune additionally causes the foreshortening and covering of vasculatures. Subsequently, the anatomical structure of the coronary conduits is hard to distinguish, and maladies are hard to evaluate.

In^[12] connected image combination strategy for the discovery of Coronary Artery vessels in Coronary Angiography. Two different methodology images were consolidated utilizing pixel image combination procedure to upgrade the inside territory of the coronary heart images. In^[13] built up a system to recognize and analyze the coronary illness utilizing encourage forward back spread neural networks. The creators accomplished 85% acknowledgment rate for their proposed algorithm. In^[14] proposed an algorithm for perceiving the coronary hallway malady using picture taking care of frameworks. The makers achieved affectability around 91% and specificity around 92% for their proposed algorithm over the game plan of 475 cardio images. The proposed algorithm was attempted on both myocardial perfusion imaging and tomographic angiography. In^[15] used Support Vector Machine (SVM) classifier to detect the coronary heart disease. This work diagnosed the coronary heart disease into low, medium, high and severe using angiogram images. The authors achieved 90% recall rate, 82.143% precision, 86.793% F-measure and 60% Overall accuracy. In^[16] proposed minimum path-based area growing algorithm for the detection of coronary vessels in angiogram images. The authors used orientated profile symmetry information technique as the extracted features for the detection process of vessels in coronary images. In^[17] proposed a framework to detect and segment coronary vessels in coronary images using Multi-scale Texture Dictionary algorithm. The texture highlights were removed from the coronary heart pictures to recognize the vessels in a mechanized way. These works deal with different strategies for approaching the segmentation task, including image-driven algorithms was proposed in^[18,19] and^[20] probabilistic atlases is discussed in^[21] and^[22]

In^[23] proposed a methodology for the classification of Coronary Heart Disease Patients from Non-coronary Heart Disease. The prediction training set accuracy was 96.86%, and testing set accuracy was 78.18%. The authors achieved cross-validation prediction accuracy of 92.67%. It used decimation-free directional filter bank technique to enhance the vessels in coronary heart images for improving the vessel detection rate. These filter banks were applied

to the image by the block-by-block manner and energy level was computed for each block. The pixels were replaced by their calculated energy values which produced enhanced images.

In^[24] proposes an automated method of blockage segmentation from coronary angiogram images using Adaptive Neuro Fuzzy Inference System (ANFIS) classifier the proposed method achieves 95.9% sensitivity, 99.9% specificity and 99.9% accuracy for blockage vessel pixel detection. In^[25] proposes an automated method of blockage segmentation from coronary angiogram images using Coactive Adaptive Neuro Fuzzy Inference System (CANFIS) classifier. The CANFIS method achieves 99.76% sensitivity, 99.9% specificity and 99.9% accuracy for blockage vessel pixel detection.

It is found that the system has an issue of vessel blockage detection in all the above techniques. So another moved strategy has projected in this research. This work reveals how to discover the determination of vessel blockage detection in various methods. In this work to instead propose a novel request strategy that consolidations are gathering correctly than past procedures

3. MATERIALS AND METHOD

Lots of researchers have been performed for the segmentation of normal and strange tissues in coronary angiogram heart pictures. Segmentation of medical image is a testing assignment because of the multifaceted nature of the images, and additionally to the absence of models of the life systems that satisfactorily catch the conceivable disfigurements in each structure. Heart tissue is an extraordinarily complex structure, and its segmentation is a basic advance for our proposed technique. In our proposed technique comprises of four stages specifically preprocessing, segmentation, feature extraction, and classification. The proposed procedure for the vessel blockage location block diagram appears in figure 2.

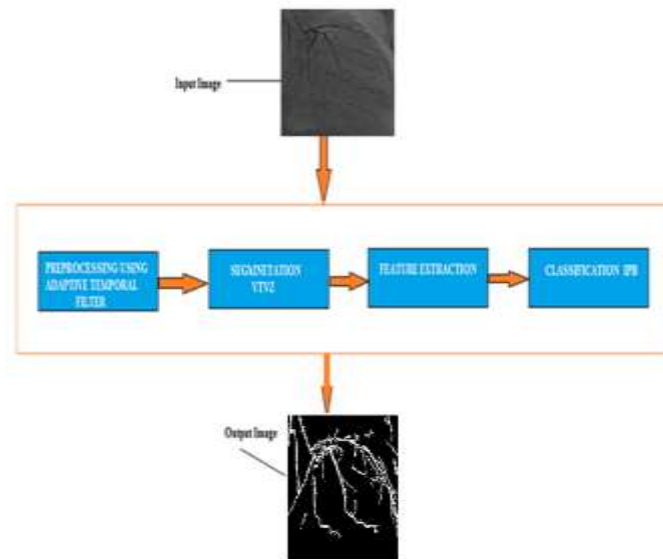


Fig 2: Block Diagram of proposed System.

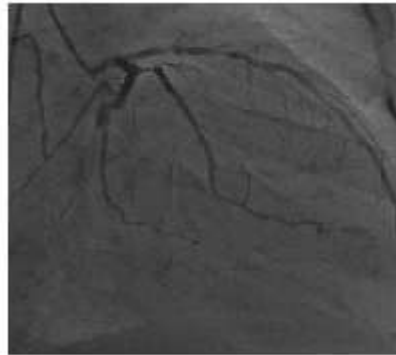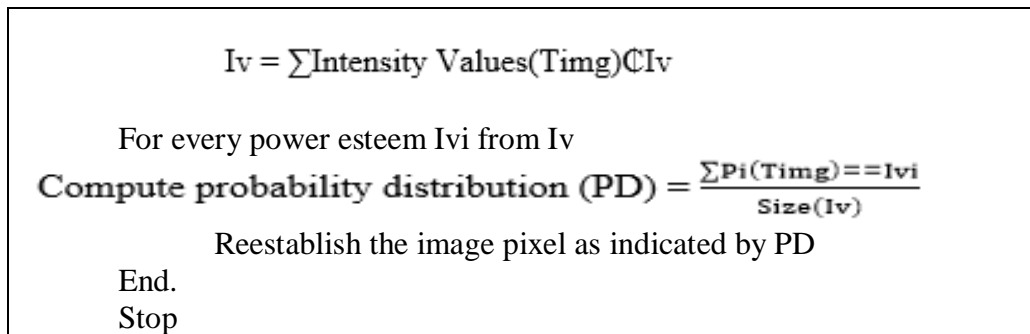
3.1 Pre-Processing Using Adaptive Temporal Filter

Pre-processing systems, for the most part, went for the improvement of the image without adjusting the data contained in an image. In this work execute a pre-processing technique for the change of coronary heart image without modifying image substance and make reasonable for additionally processing. The pre-processing method comprises of deciding the pixels outside the aperture that are neighbors to pixels inside the opening and supplanting every one of their esteems with the mean estimation of their neighbors inside the aperture. In this work, an adaptive temporal filter is utilized for preprocessing. In adaptive temporal filtering, the result of the image is weighted with an aggregate of information pixels. The estimation of a filter sub-image is alluded as coefficients, instead of pixels. Adaptive filtering term is the filtering tasks that are performed straightforwardly on the pixels of an image. The filter is a cover of weights masterminded in a rectangular example. The procedure is one of sliding the mask and performing increase and collect activity on the pixels secured by the mask.

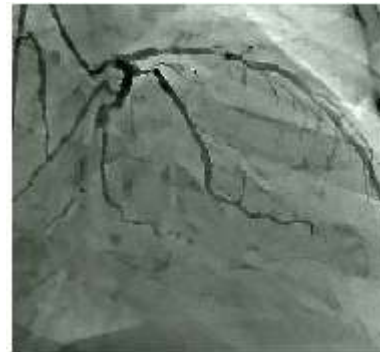$$\text{Adaptive Temporal Filtering} = g(x, y) = \sum_{s=-a}^a \sum_{t=-b}^b W(s, t) f(x + s, y + t) \dots (1)$$

3.1.1 Adaptive Temporal Filtering Algorithm Steps

Methodology: Adaptive Temporal Filter
 Info: Coronary heart image
 Output: Preprocessed image Pimg.
 Begin
 Catch Image Img.
 Preprocess the image Img.
 Distinguish an arrangement of all interesting force estimations of image Timg.



3a) Input image



3b) Preprocessed image

Fig 3: Result of Preprocessing.

The above figure 2 indicates result correlation of input and preprocessed image utilizing adaptive temporal filtering. When contrasted with Input image the preprocessed image demonstrates the better view without commotion. The above-talked algorithm plays out the histogram leveling of the information image caught through the gadget and enhances the nature of information image acquired.

3.2 Versatile Threshold Vector Zone (VTVZ) Vessel Blockage Segmentation

The preprocessed image is switched and prepared by the morphological activity. A nearby morphological operation is utilized for the segmentation reason. In this work, adaptable threshold Vector Zone Segmentation procedure is being used for blood vessel location. The nearby morphological methodology is a procedure that morphological expansion took after by erosion. The essential factor or component which is essential for closing activity is organizing segment. Two sorts of arranging components are available, initial one is level organizing component and the second one is non-level organizing component. The VTVZ Segmentation relies upon the pixel esteem, choice level and features of the angiogram image. The VTVZ has been utilized to expand the perception of differentiation of the low and high finishes of the image histogram. The algorithm steps are given beneath.

3.2.1 Algorithm

Step1: Resampling of the angiogram image with the motivation behind conveying its measurement to the measurement of the coronary image.

Step2: Geometric and radiometric redress of the info images.

Step3: Contrast and diagram adjustment of the information images.

Step4: VTVZ segmentation.

Step5: Converting of the acquired angiogram image ([ANF]_MOD) into the HSV shading model ([HSV]_MUL).

Step6: Altering the R, G and B outfits of the heart image into HSV instruments ([HSV]_MUL).

Step7: The subsequent stage of development of another image is substitution the brilliance part V of a [HSV]_MUL image with the splendor segment of [HSV]_MOD and changing over the outcome from the HSV shading model to the RGB shading model.

Step8: Decorrelation of the new heart image as per the picked algorithm:

$$f_{RGB}(r) \rightarrow f_{xyz}(r) \dots (2)$$

Step9: A pyramidal deterioration with the given wavelet premise to the given disintegration level (L) of the shine channel (X)

$$f_x(r) = C_L^X(r) + \sum_{i=1}^L d_x^{i,1}(r), d_x^{i,2}(r), d_x^{i,3}(r) \dots (3)$$

Step 10: A pyramidal deterioration with the given wavelet premise to the given disintegration level (L) of the coronary heart image

$$f_p(r) = C_L^X(r) + \sum_{i=1}^L d_x^{i,1}(r), d_x^{i,2}(r), d_x^{i,3}(r) \dots (4)$$

Step 11: Development of new segments of the decay as per the accompanying tenets of unification of coefficients.

$$APP \frac{L}{X}(r) = C_L^X(r),$$

$$Det_x(r) = \sum_{i=1}^L \begin{bmatrix} A^{i,1} d_x^{i,1}(r) + B^{i,1} d_p^{i,1}(r) \\ A^{i,2} d_x^{i,2}(r) + B^{i,2} d_p^{i,2}(r) \\ A^{i,3} d_x^{i,3}(r) + B^{i,3} d_p^{i,3}(r) \end{bmatrix} \dots (5)$$

Where

$APP \frac{L}{X}$ = approximating wavelet components of the new vessel blockage image.

Det_x = detailing wavelet components of the new vessel blockage image.

In the wake of segmentation, the blood vessels of a coronary angiogram are removed. To express the usage procedure of the proposed strategy unmistakably, the outline of the proposed system for the segmentation of angiograms appears in figure 4

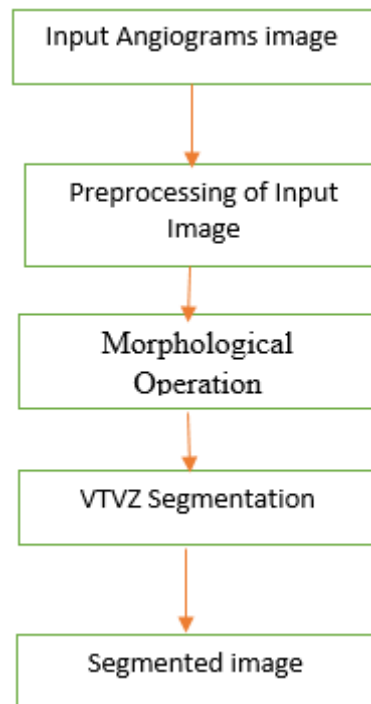


Fig. 4: Morphological Processing Steps.

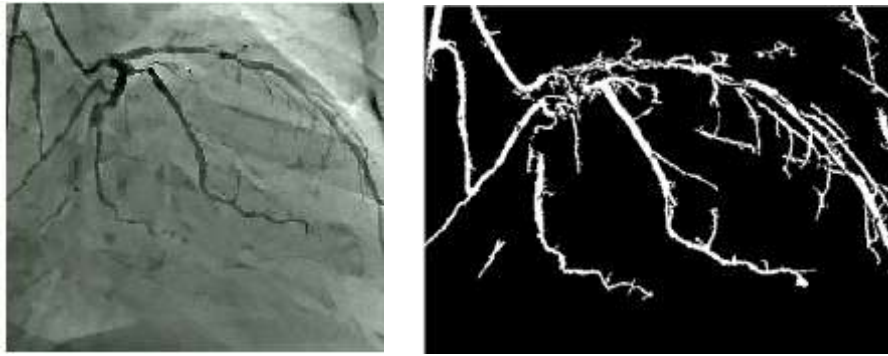
3.2.2 Morphological Processing Steps

Step 1: The input coronary angiogram image is perused.

Step 2: For preprocessing Top morphological Hat task is done on the info image.

Step 3: Morphological Closing task, i.e., Dilation and erosion are connected to the image with the circle formed organizing components.

Step 4: The image acquired after a morphological activity is then edge utilizing VTVZ segmentation.



5a) Preprocessed Image.

5b) Segmented Image.

Fig. 5: Segmentation Result.

Figure 4 shows the segmentation result utilizing VTVZ method. The segmented outcomes make the centroid in light of the potential estimation of the data focuses. as contrasted with other customary innovation the VTVZ segmentation gives a superior precision.

3.3 Feature Extraction: Diagonis Zone Unsupervised Vector

After segmentation, the Feature esteems are separated given the closeness measure of every pixel arrangement at various zones. The inspiration for utilizing numerous zones (inside, limit, and encompassing lesion) and the picked features depends on the way that the encompassing shortcoming attributes. The fault is comprised of a thick improving edge; the fault border is characterized as unpredictable or poorly marked edges.

The feature is separating the coronary heart images and recognizing the fault as the focal zone; the proposed framework will isolate the divided lesion area vector (V_0) into two ROIs (where $V_0 = V_1 \cup V_2$). V_1 is the region of the fault and characterized as a zone where over 70% of the fault pixels has situated inside the board. Something else, the image has considered a fault region (V_2).

3.3.1 Algorithm

Input: Segmented Feature Values (SFv), segmented lesion (SFV0).

Output: Extracted Feature Vectors LZfv- V_1 (inside fault), V_2 (fault border), V_3 (neighbouring fault).

Procedure

Step 1: For each Segmented Feature Values SF_v

SET Dia = minimum diameter of SFV₀;

SET Feature element, S_IN = Dia*0.3;

Step 2: Estimate the feature vectors

SET V1 = Erode (SFV₀, S_IN);

SET V2 = SFV₀-V1;

Step 3: For each Segmented Feature Values SF_v

SET Feature element, S_OUT = 1.8* S_IN;

Step 4: Estimate the feature vectors

SET = Dilate (SFV₀, S_OUT) SF_v;

SET V3 = - SFV₀;

Step 5: RETURN V1, V2, V3.

Step 6: Construct Lesion Zone Feature Vector values

$$LZF_v = \int_{j=1}^k (V1 \cap V2 \cap V3) \in D_s(j)$$

Step 6: Stop.

By utilizing diagnose zone unsupervised vector 12 features were removed for proposed strategy, few of them are portrayed as takes after.

3.3.2 Energy

The vitality is the measure of consistency between the pixels run = [0, 1].The consistency of the pixel has communicated

$$Energy = \sum_{i,j} p(i,l)^2 \dots (6)$$

3.3.3 Contrast

Contrast is the measure of the distinction in luminance to make protest recognizable.

Range = [0,1].

$$contrast = \sum_{i,j} |i - l|^2 p(i,j) \dots (7)$$

3.3.4 Correlation

Correlation is the measure of the connection between the neighbor pixels. Range = [-1, 1].

$$\text{correlation} = \sum_{i,j} \frac{(i,j)p - \mu_x \mu_y}{\sigma_x \sigma_y} \dots (8)$$

3.3.5 Homogeneity

The homogeneity measures of the closeness of the component appropriation in finding zone unsupervised vector. Range= [0,1]

$$\text{Homogeneity} = \sum_{i,j} \frac{1}{1+(i-j)^2} P(i,j) \dots (9)$$

Where I, j are pixel and p (I, j) is the pixel esteem. Along these lines to arrange the image as ordinary or unusual, the middle of the images are gained, preprocessed, the element extricated by utilizing diagnosis zone unsupervised vector strategy.

3.4 Intensive Pragmatic Blossoms Classification

The classifier is utilized to order blockage influenced zone composes from unique images. For straightforwardness, solid augmented blossom classifier is used here. It takes set of pictures and predicts for each information image has a place with which of the two classes of tissue influenced and without a controlled image. The motivation behind IPB is to make angiogram images to isolate two classes with a most extreme hole between them. In our proposed framework, an output of segmentation is given as a contribution to concentrated businesslike blooms classifier which takes preparing information, testing information and gathering data which groups the given input image.

Algorithm

Input: Input Image

Output: Class S

Start

Area S= Perform vector threshold based absorption Estimation

Image Img = Preprocess Image from datasets (Adaptive Temporal Filter)

Image Img = segmentation Image (Versatile Super threshold Vector Zone)

KSDF = Intensive Pragmatic Blossoms classification

If KSDF <Th1> then

Area A = S

Else KSDF <Th2> then

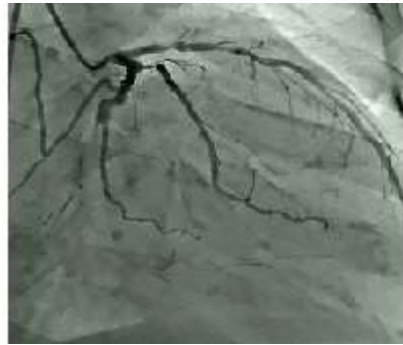Area B = S

Else if KSDF <Thn> then

Area N = S

End Stop.

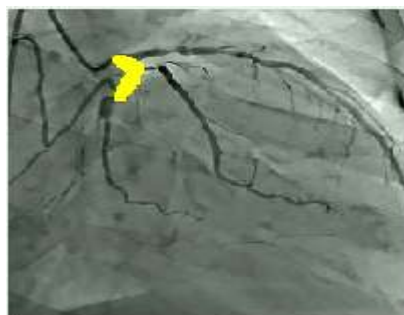The classification strategy initially plays out the vector-based vessel blockage image estimation and afterward catches the image to preprocess and segment the image. At that point, the procedure processes the classification algorithm to arrange the outcomes given beneath.



6a) Input Image.



6b) Segmented Image.



6c) Blockage Identified Image.

Fig. 6: Classification Result.

The above figure 6 demonstrates the grouping consequences of blockage recognizable proof in the proposed framework. The execution of the grouping has assessed concerning order exactness, accuracy, recall, and F-measure from the perplexity framework of classification. The estimations have processed by utilizing the conditions depicted beneath with the

accompanying conventions. TP (True Positive) = Positive units named positive. True Negative (TN) = Negative examples delegated negative. FP (False Positive) = Negative examples delegated positive. FN (False Negative) = Positive examples named negative.

Precision: It is the proportion of number of positive examples accurately ordered to the aggregate number of tests in a class.

$$precision = \frac{Tp}{Tp+Fp} \dots (10)$$

Recall: It is the proportion of some positive examples effectively arranged to the aggregate number of tests named positive.

$$Recall = \frac{Tp}{Tp+Fn} \dots (11)$$

F-measure: It is the consonant mean of accuracy and review given by the condition underneath.

$$F_{measure} = \frac{2*precision+recall}{precision+recall} \dots (12)$$

Accuracy: It is the aggregate number of tests accurately ordered to the aggregate number of tests delegated given by the condition beneath.

$$Accuracy = (TP + TN)/(Tp + Tn + Fp + fn) \dots (13)$$

The fault classification is performed using both VTVZ segmentation and diagnosis zone unsupervised vector feature extraction technique. The method first performs the region based coronary image estimation and then captures the image to preprocess and segment the image. Then the method computes the classification algorithm to classify the fault area.

4. RESULTS AND DISCUSSION

The proposed algorithm is tried on York University open access dataset which contains 7000 typical coronary heart pictures and 980 anomalous coronary heart pictures. In this work, two separate datasets are built from this open access dataset as preparing and testing by extricating 350 typical and 300 unusual coronary pictures from this open access dataset. MATLAB R2017a is utilized as a part of this work to reenact the proposed calculation, and Intel Pentium Core-2 Duo 2.4GHz with 2 GB RAM is utilized as the equipment particulars. The parameters Sensitivity (Se), Specificity (Sp), Positive Predictive esteem (PPV), Negative

Predictive Value (NPV) and Accuracy (Acc) are utilized to assess the execution of the proposed technique.

$$Se = TR_PO / (TR_PO + FA_NE) \quad (14)$$

$$Sp = TR_NE / (TR_NE + FA_PO) \quad (15)$$

$$PPV = TRPO / (TRPO + FA_PO) \quad (16)$$

$$NPV = TR_NE / (TR_NE + FA_NE) \quad (17)$$

$$Acc = (TRPO + TR_NE) / (TRPO + FA_NE + TR_NE + FA_PO) \quad (18)$$

Though TR_PO is True Positive which speaks to the accurately distinguished blockage vessel pixel, TR_NE is the True Negative which speaks to the recognized efficiently non-blockage vessel pixel, FA_PO speaks to the dishonestly identified blockage vessel pixel, and FA_NE speaks to the erroneously distinguished non-blockage vessel pixel. The possibility table is built by relating TR_PO, TR_NE, FA_PO, and FA_NE, as delineated in Table 1 utilizing adaptable threshold vector zone vessel blockage segmentation.

Table 1: Performance results of the proposed methodology.

Performance analysis parameters	Estimated values (%)
Sensitivity	99.99
Specificity	99.99
Positive Predictive Value	97.31
Negative Predictive Value	99.99
Accuracy	99.99

The morphological parameters as border, zone, width, and stature, are assessed on the portioned tumor zone in cervical pictures. The border computation of the portioned growth zone in a cervical picture depends on the span 'r,' and the morphological parameter for the computation of edge is given by the accompanying condition as,

$$\text{Perimeter} = 2\pi r \dots (19)$$

The estimated morphological values are depicted in Table 2.

Table 2: Morphological analysis.

Parameters	Morphological values
Perimeter(μm)	868.63
Width(μm)	109
Height(μm)	110

Table 3: Performance comparison of proposed and conventional methodologies.

Performance Analysis Parameters	Sensitivity (%)	Specificity (%)	Accuracy (%)
Proposed work IPB	99.99	99.99	99.9
Proposed Work CANFIS	99.76	99.96	99.95
Proposed Work ANFIS	95.9	99.9	99.9
Danilo Neglia <i>et al.</i>	91	92	92.1
Wiharto <i>et al.</i>	82	90	90.5

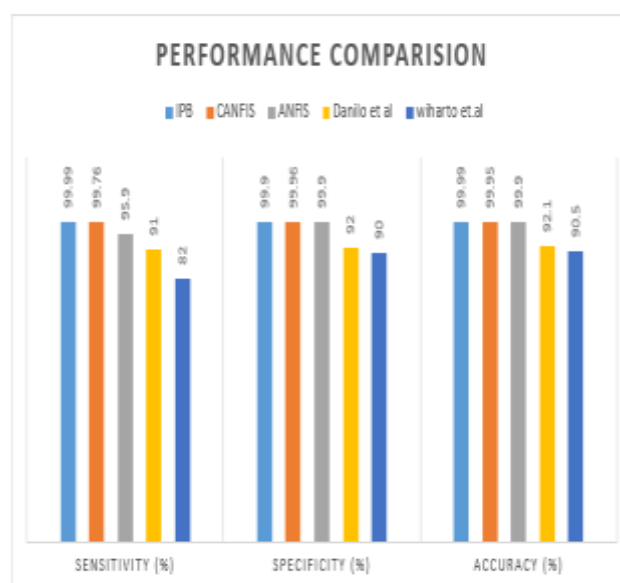

Fig. 7: Performance Comparison of proposed and existing Systems.

Table 3 and figure 7 demonstrates the correlations of the proposed system for blockage vessel location in coronary heart pictures with traditional strategies. The proposed IPB strategy accomplishes 99.99% affectability, 99.99% specificity and 99.99% precision for blockage vessel pixel discovery. The customary techniques as (of) Danilo Neglia *et al.* (2015) accomplished 91% affectability and 92% specificity while of Wiharto *et al.* (2015) got 82 % affectability, 90 % specificity. It is seen from the table that the proposed blockage vessel pixel discovery technique is better than the customary strategies.

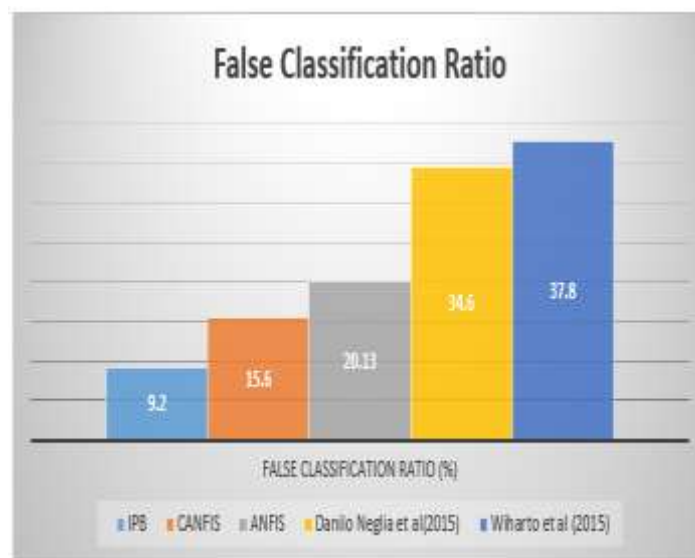


Figure 8: Comparison of various methods in a false ratio.

Figure 8 demonstrates the examination of results obtained from various strategies for false classification. When contrasted with all systems the proposed methodology has less mean rate which is inconsequential.

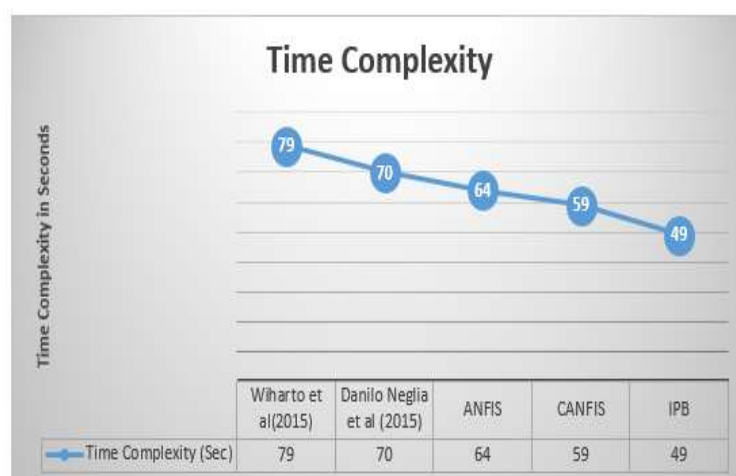

Figure 9: Comparison of time complexity of different methods.

Figure 9 demonstrates the correlation of different strategies on time multifaceted nature, and it portrays that the proposed strategy has less time complexity than others. From the above examination played out, the proposed technique has been assessed with different parameters and has delivered helpful outcomes with all elements of optical properties and order.

5. CONCLUSION

The vessel blockage image segmentation has been discussed in this work. In this work, an adaptive temporal filter is associated with smooth the picture by emptying the commotion. Adaptable threshold clustering technique is used from the preprocessed picture, where the gathering of objects is performed. In this work, computer-aided automatic detection of blockage in coronary heart images using IPB and compared with ANFIS and CANFIS classifier is proposed. As compared to other conventional technique the proposed IPB technique produces an advantageous result. The spatial domain coronary heart image is converted into a multi-resolution image using temporal filter transform after preprocessing the image. Then, features are extracted from this multiresolution image and these features are trained and classify using IPB classifier to detect the coronary heart image which contains blockage. The proposed method achieves 99.98% sensitivity, 99.975% specificity and 99.99% accuracy for blockage pixel detection.

REFERENCES

1. M. G. Tsipouras, T. P. Exarchos, D. I. Fotiadis, A. P. Kotsia, K. V. Vakalis, and K. K. Naka et al., "Automated diagnosis of coronary artery disease based on data mining and fuzzy modeling," *IEEE Trans. Inf. Technol. Biomed.*, 2008; 12: 447–458.
2. S. Josephson, S. Bryant, H. Mak, S. Johnston, W. Dillon, and W. Smith, "Evaluation of carotid stenosis using CT angiography in the initial evaluation of stroke and TIA," *Neurology*, 2004; 63: 457–460.
3. G. T. Lau, L. J. Ridley, M. C. Schieb, D. B. Brieger, S. B. Freedman, and L. A. Wong et al., "Coronary artery stenoses: Detection with calcium scoring, CT angiography, and both methods combined 1," *Radiology*, 2005; 235: 415–422.
4. M. A. Cordeiro, A. C. Lardo, M. S. Brito, M. A. R. Neto, M. H. Siqueira, and J. R. Parga et al., "CT angiography in highly calcified arteries: 2D manual vs. modified automated 3D approach to identify coronary stenoses," *Int. J. Cardiovas. Imag*, 2006; 22: 507–516.

5. A. C. Dumay, J. Reiber, and J. Gerbrands, "Determination of optimal angiographic viewing angles: Basic principles and evaluation study," *IEEE Trans. Med. Imag.*, 1994; 13: 13–24.
6. S. Mavrogeni, G. Papadopoulos, M. Douskou, S. Kaklis, I. Seimenis, and P. Baras et al., "Magnetic resonance angiography is equivalent to X-Ray coronary angiography for the evaluation of coronary arteries in Kawasaki disease," *J. Amer. College Cardiol.*, 2004; 43: 649–652.
7. U. Solzbach, U. Oser, M. Rombach, H. Wollschläger, and H. Just, "Optimum angiographic visualization of coronary segments using computer-aided 3D-reconstruction from biplane views," *Comput. Biomed. Res.*, 1994; 27: 178–198.
8. Y. Sato, T. Araki, M. Hanayama, H. Naito, and S. Tamura, "A viewpoint determination system for stenosis diagnosis and quantification in coronary angiographic image acquisition," *IEEE Trans. Med. Imag.*, 1998; 17: 121–137.
9. S. Sakamoto, Y. Kiura, M. Shibukawa, S. Ohba, K. Arita, and K. Kurisu, "Subtracted 3D CT angiography for evaluation of internal carotid artery aneurysms: Comparison with conventional digital subtraction angiography," *Amer. J. Neuroradiol.*, 2006; 27: 1332–1337.
10. G. Tipper, "Detection and evaluation of intracranial aneurysms with 16-row multislice CT angiography," *Clinical Radiol.*, 2005; 60: 565–572.
11. D. E. Hyde, A. J. Fox, I. Gulka, P. Kalapos, D. H. Lee, and D. M. Pelz et al., "Internal carotid artery stenosis measurement comparison of 3D computed rotational angiography and conventional digital subtraction angiography," *Stroke*, 2004; 35: 2776–2781.
12. Julien Plessis, KarineWarinFresse, Zachary Cahouch, ThibautManigold. Value of Image Fusion in Coronary Angiography for the Detection of Coronary Artery Bypass Grafts. *Journal of the American Heart Association*, 2016; 5(6): 245–256.
13. Ebenezer ObaloluwaOlaniyi, OyebadeKayodeOyedotun. Heart Diseases Diagnosis Using Neural Networks Arbitration. *International Journal of Intelligent Systems and Applications*, 2015; 12: 75-82.
14. Danilo Neglia, Daniele Rovai, Chiara Caselli, MikkoPietila. Detection of Significant Coronary Artery Disease by Noninvasive Anatomical and Functional Imaging. *Cardiovascular Imaging*, 2015; 8(3): 1–10.
15. Wiharto, HariKusnanto, Herianto. Performance Analysis of Multiclass Support Vector Machine Classification for Diagnosis of Coronary Heart Diseases. *International Journal of Computational Science & Applications*, 2015; 5(5): 27–37.

16. Qing Cao, Yang Chen, Guanyu Yang, Christine Toumoulin, HuazhongShu, LiminLuo. Coronary vessel extraction method using an improved minimum path-based area growing. 6th International Conference on Biomedical Engineering and Informatics, 2013: 127 – 131.
17. Ali Zifan, Brian E. Chapman Automatic Detection of Coronary Vessels Using Multi-scale Texture Dictionaries IEEE Second International Conference on Healthcare Informatics, Imaging, and Systems Biology, 2012; 1–15.
18. S Huang, J Liu, LC Lee, SK Venkatesh, LLS Teo, C Au, WL Nowinski, An image-based comprehensive approach for automatic segmentation of left ventricle from cardiac short axis cine MRI images. *J. Dig. Imaging*, 2010: 1–11.
19. AB Redwood, JJ Richard, A Robb, Semiautomatic segmentation of the heart from CT images based on intensity and morphological features. In *Proc SPIE*, 2005; 5747: 1373–1719
20. JP Morin, C Desrosiers, L Duong, Image segmentation using random-walks on the histogram. In. *Proc. SPIE*, 2012; 83(14): 1–8.
21. M Lorenzo-Valdes, GI Sanchez-Ortiz, AG Elkington, RH Mohiaddin, D Rueckert, Segmentation of 4D cardiac MR images using a probabilistic atlas and the EM algorithm. *Med. Image Anal*, 2004; 8: 255–265.
22. Isgum, Multi-Atlas-based segmentation with local decision fusion – Application to cardiac and aortic segmentation in CT scans. *IEEE Trans. Med. Imaging*, 2009; 28(7): 1000–1010.
23. Hongzong, S, Tao, W, Xiaojun, Y, Huanxiang, L, Zhide, H, Mancang, L, BoTao, F. Support Vector Machines Classification for Discriminating Coronary Heart Disease Patients from Non-coronary Heart Disease. *West Indian Medical Journal*, 2007; 56(5): 451–457.
24. P. Rajesh Kumar and K. Murugesan “An Automated Screening System for Vessel Blockage Segmentation in Coronary Angiogram Images Using ANFIS Classifier” *Int. J. Bio-Inspired Computation*, 2017.
25. Rajesh Kumar, P & Murugesan, K. “Computer Aided Segmentation of Blockages in Coronary Heart Images Using Canfis Classifier”, *Wireless Personal Communications*, 2018. DOI: 10.1007/s11277-018-5512-0.