



**A REVIEW OF FROZEN SHOULDER AND ROTATOR CUFF
TENDONITIS: MOST PREVAILING MUSCULOSKELETAL
DISORDERS OF SHOULDER JOINT**

Nikita Sharma*¹ and Apoorva Chaudhary²

¹Student, Amity School of Engineering and Technology Amity University Haryana, Manesar, Haryana, India.

²Assistant Professor, Amity School of Engineering and Technology Amity University Haryana, Manesar, Haryana, India.

Article Received on 07/04/2018

Article Revised on 28/04/2018

Article Accepted on 18/05/2018

***Corresponding Author**

Nikita Sharma

Student, Amity School of
Engineering and
Technology Amity
University Haryana,
Manesar, Haryana, India.

ABSTRACT

Musculoskeletal disorders in the shoulder region are increasing day by day and their impact is persistent. Musculoskeletal conditions are the most common cause of physical disability and severe long term pain, which are affecting hundreds of millions of people around the world. Of all the joints in the human body, Glenohumeral joint (Also known as shoulder joint) has the greatest range of motion. Therefore, it is

capable of carrying out intricate movements and is greatly significant in daily living and work related activities. Recent research shows that shoulder pain is one of the most common regional musculoskeletal complaint in general population as well as in work environment. In this review paper we are going to talk about the most common musculoskeletal disorders in the shoulder which are Frozen Shoulder and Rotator cuff Tendonitis.

KEYWORDS: Musculoskeletal Disorders, Rotator Cuff Tendonitis, Adhesive Capsulitis, Glenohumeral Joint.

INTRODUCTION

Musculoskeletal disorders are those that affect human musculoskeletal system which consists of joints, ligaments, muscles, tendons, nerves and supporting structures like limbs, neck and

back. Musculoskeletal pain has become an inescapable part of human experience and Shoulder is among the most prevailing sites for musculoskeletal complaint. Middle aged and elderly people are more vulnerable to shoulder pain (Badley and Tennant, 1992). Shoulder pain may occur due to the anatomical structures that are associated with the shoulders, including rib cage, diaphragm and neck. The pain may also arise due to one's occupation, which is also one of the common reasons for people to consult a medical professional.

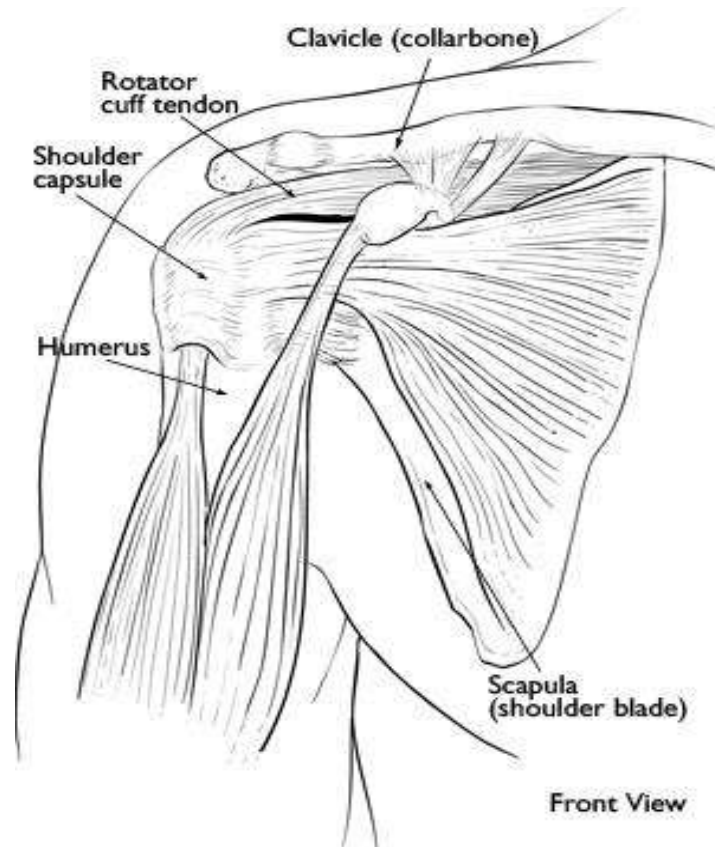


Figure 1: Front view of the shoulder.

Frozen Shoulder (also known as Adhesive Capsulitis) arise when the shoulder capsule thickens and becomes stiff. Furthermore, adhesions (stiff bands of tissue) develop and the amount of synovial fluid decreases. It mostly occurs in middle aged people and is more prominent in women than men.

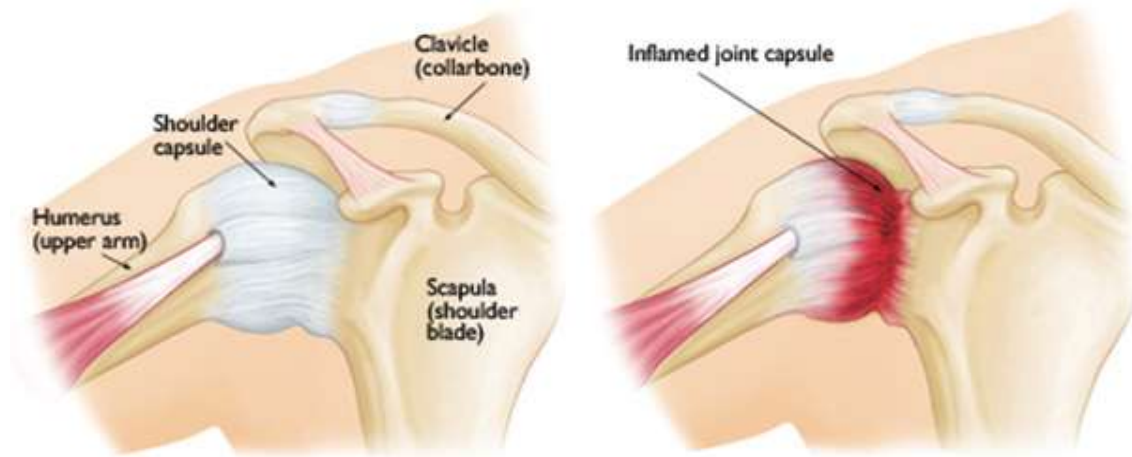
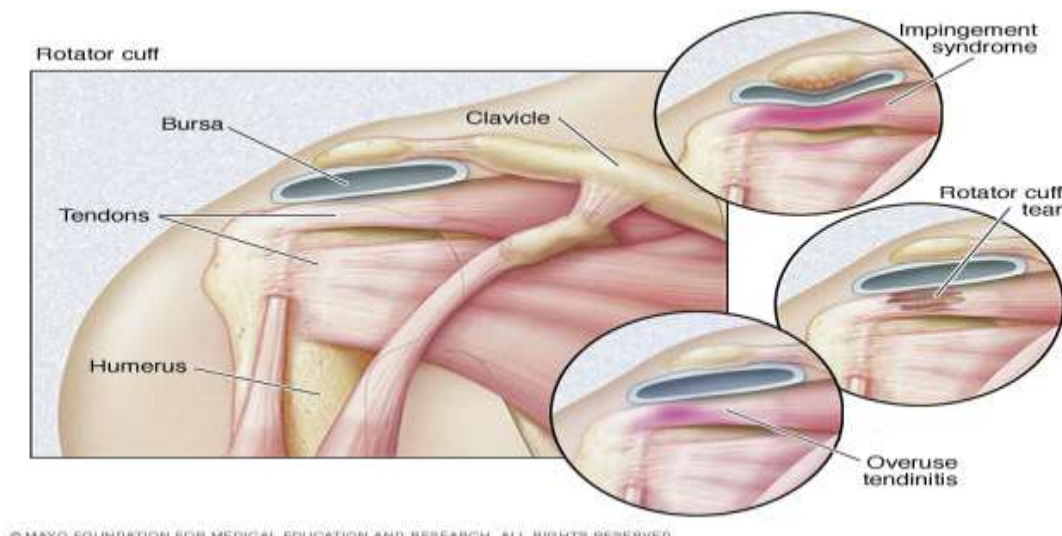


Figure 2: In frozen shoulder, the smooth tissues of the shoulder capsule become thick, stiff, and inflamed.

Rotator Cuff Tendinitis (also known as Impingement Syndrome) is the inflammation of tendons in the shoulders. It occurs in young athletes and middle aged people. It is one of the most common source of pain in shoulders. The pain can be as a result of:

1. Tendonitis: This happens when rotator cuff tendons is irritated or damaged due excessive pressure on the acromion or due to intrinsic tendon pathology.
2. Bursitis: It is when the bursa becomes inflamed and gets swollen with more fluid causing pain.
3. Impingement: When you raise your arm to the shoulder height, the space between the acromion and rotator cuff becomes narrow. Consequently, the acromion rubs against (or "impinge" on) the tendon and the bursa, causing irritation and pain.



© MAYO FOUNDATION FOR MEDICAL EDUCATION AND RESEARCH, ALL RIGHTS RESERVED.

Figure 3: Rotator Cuff Tendinitis (Riley et al, 1989).

Musculoskeletal Disorders of Shoulders

1. Frozen Shoulder

The term frozen shoulder was coined by Codman in 1934 which is basically an orthopaedic condition. He described this condition that has symptoms like shoulder pain and discomfort which is slow in onset and is located around the deltoid insertion. Patients suffering from frozen shoulder are unable to sleep on the affected side. This condition can be generally classified into two categories: primary, in this no causes are seen, and secondary, where cause can be discerned with the help of following parameters like clinical examination, radiographic appearances and history (Wong and Tan, 2010). The age group that is mainly affected by frozen shoulder is 40-60 years with females being more vulnerable (Wong and Tan, 2010). It has been seen that people already tormented with hyperthyroidism, hypothyroidism, Parkinson's disease, cardiovascular disease, long-lasting shoulder immobility (which could be because of surgery, overuse of the joint and trauma), and diabetes have high prevalence rate (Pal et al, 1986; Riley et al, 1989). Most common cause of frozen is immobilization, wherein frozen shoulder can develop after a shoulder has been immobilized for a period of time due to surgery, a fracture, or other injury.

Pathology of frozen shoulder revealed the presence of chronic inflammatory cells and fibroblasts proliferation (Hand et al, 2007). The advancement of primary Frozen Shoulder take place through three clinical phases.^[1] The painful phase, in this there is onset of pain in the shoulder which is mostly worst at night and when lying on the affected side, and it continue up to 2-9 months.^[2] Frozen or Stiffening phase, in this the pain stays the same as in the earlier phase and the patients face difficulty in daily simple activities. Also, in this phase, the stiffness advances and will probably lead to muscle wasting due to inactivity. This phase lasts for 4-12 months.^[3] Thawing phase, in this phase the patient experiences improvement in the pain and also an increase in the range of movement. This phase lasts for 5-12 months (Wong and Tan, 2010).

The Three stages of Frozen Shoulder Progression	
Painful Stage	Shoulder pain is the hallmark of this stage. It starts gradually and progressively worsens.
Frozen Stage	Pain may reduce in this stage, although shoulder stiffness and restriction increase. Shoulder range of motion is dramatically reduced.
Thawing Stage	This stage is characterized by spontaneous “thawing.” The motion will gradually increase and the shoulder will be more responsive to stretching exercises and treatment.

Figure 4: Three Stages of Frozen Shoulder Progression.

2. Rotator cuff tendonitis

To understand rotator cuff tendonitis first we need to understand what is rotator cuff. So, the humerus (the upper arm bone) is associated to the shoulder by muscles and tendons. The rotator cuff is composed of four muscles—subscapularis, supraspinatus, infraspinatus, and teres minor—and their musculotendinous attachments. The rotator cuff is formed by these four muscle-tendon groups, which controls rotation of the arm away from the body and it also stabilises the shoulder. The cuff part comes from the four tendons merging together to form a “cap” or “hood” around the head of the humerus. The head of the humerus basically acts as the ball in the ball and socket joint, which is the shoulder joint. This joint allows circumduction, but this may be limited by tendonitis in the cuff. Rotator cuff tendonitis is also known as impingement bursitis or biceps tendonitis. It refers to the painful and swollen condition of cuff tendons and the surrounding bursa. Bursa is a soft sack that contains some amount of fluid and helps in cushioning the joint. In 1834 Smith was the first person to describe rupture of the rotator cuff tendon. Afterwards, better characterisation of degenerative changes of rotator cuff was put forward by Duplay (1872), Von Meyer (1924), Codman (1934), and Neer (1972). (Neer, 2005).

The pathology of the rotator cuff can result from intrinsic and extrinsic factors. Some examples of extrinsic factors include overuse injuries from repetitive lifting, throwing, pulling, pushing or traumatic tear in tendons from a fall or accident. On the other hand, examples of intrinsic factors include calcific invasion of tendons, poor blood supply, and degeneration with aging (Bigliani *et al.*, 1986; Uthoff and Sano, 1997; Gerber and Krushell, 1991; Sallay *et al.*, 2007; Ward *et al.*, 2007; Via *et al.*, 2013). Dysfunctioning of rotator cuff is

basically a continuum of pathology which ranges from tendonitis to bursitis to partial tear to full tear in one or more of the tendons. Even though the earlier stages can be resolved with proper care, complete tearing of the tendon can be very challenging. Most of these tears transpire at the tendon-to-bone junction. Since, there is poor blood supply in this area, an injury to the tendon at this site is improbable to heal well. Furthermore, because of the constant resting tension in the muscle-tendon unit, pulls any detached fibers away from the bone, averting their reattachment. In the end, the joint fluid from inside the shoulder may ooze into the gap that is created by the tear, which will prevent the normal healing process. It has been observed that 65-70% of all the shoulder pain is because of rotator cuff disease. Mostly the causes of rotator cuff disease is related to overloading, degeneration of cuff with aging, Instability of acromioclavicular and glenohumeral joint, musculoskeletal diseases resulting in wasting of cuff muscles, muscular imbalance because of adverse anatomical features, and ischaemia (Shanahan and Sladek, 2011).

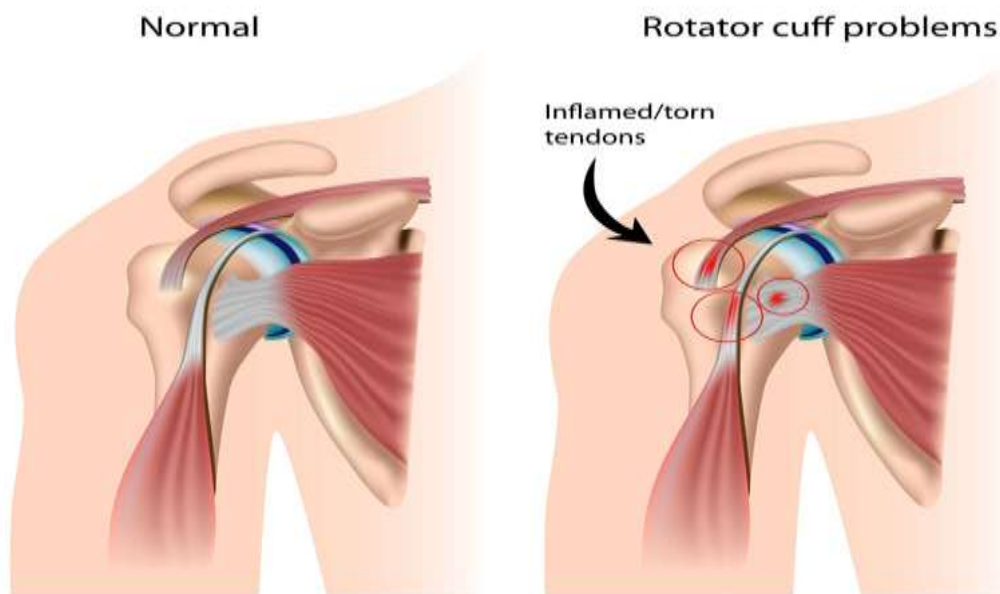


Figure 5: Difference between normal Tendons and Inflamed Tendons.

Prevalence

Below fig. 6 summarises that according to the diagnostic schedule the specific disorders with highest prevalence rates were adhesive capsulitis (an estimated 8.2% of men and 10.1% of women) and rotator cuff tendinitis (4.5% of men and 6.1% of women) (Walker-Bone et al., 2004).

Diagnosis	Men (n = 2,696)		Women (n = 3,342)	
	No. of cases in sample (n = 777)†	Prevalence (%) in general population‡	No. of cases in sample (n = 1,183)†	Prevalence (%) in general population‡
Shoulder				
Adhesive capsulitis	137	8.2	201	10.1
Rotator cuff tendinitis	76	4.5	121	6.1
Bicipital tendinitis	11	0.7	14	0.7
Subacromial bursitis	17	0.8	20	1.3
AC joint dysfunction	13	1.0	25	1.0
Any of these specific shoulder disorders	148	9.7	217	10.9
Nonspecific shoulder pain	32	2.1	50	2.5

Figure 6: This table shows that Adhesive Capsulitis (Frozen Shoulder) and Rotator Cuff Tendinitis are the most prevalent musculoskeletal disorders in shoulders ((Walker-Bone *et al.*, 2004).

Figure 7 below illustrates the age and sex specific prevalence rates for disorders of shoulder in the general population. It can be seen that among men the rate of prevalence of nonspecific pain in shoulder tended to increase with age. On the contrary, prevalence of nonspecific shoulder pain among women peaked in the 45–54 year age stratum (Walker-Bone *et al.*, 2004).

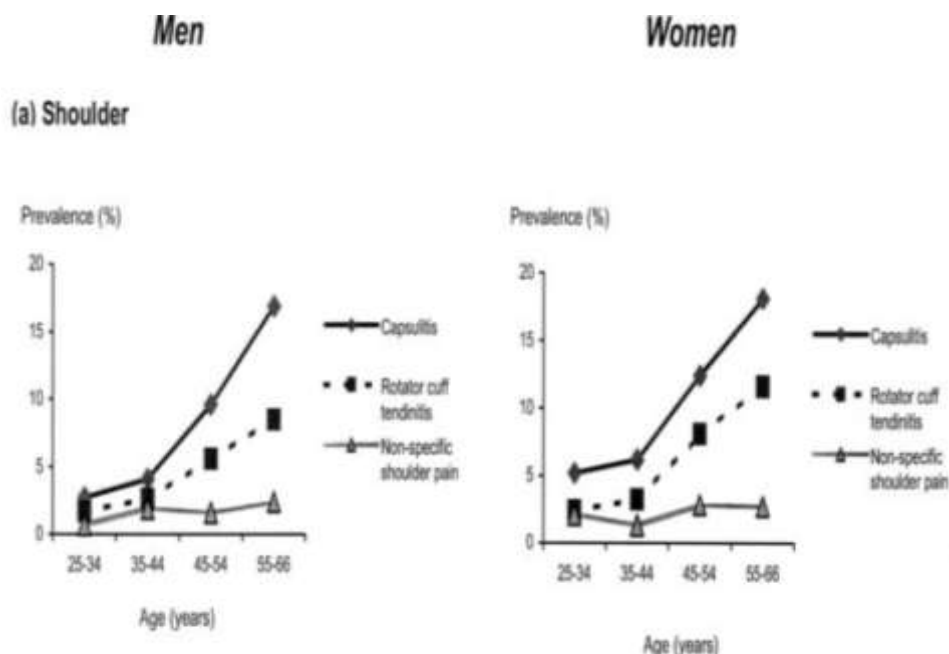


Figure 7: The estimated prevalence in the general population of specific disorders and nonspecific pain by age and sex at the shoulder (Walker-Bone *et al.*, 2004).

CONCLUSION

Undoubtedly, the Frozen Shoulder and Rotator Cuff Tendonitis are the most common musculoskeletal disorders of the shoulder joint. The review has indicated their prevalence due to various reasons and particularly due to wrong posture and prolonged working conditions. These disorders are also associated with sedentary lifestyle, which invariably leads to a level of inactivity among the masses. It is also evident that these disorders are more prevalent in women than men. Considering the occurrence of these disorders more specific diagnostic methods and treatment are required to be established to reduce its widespread impact and suffering. Efforts should also be made to address these musculoskeletal disorders through preventive medicine.

REFERENCES

1. Badley EM, Tennant A “Changing profile of joint disorders with age: findings from a postal survey of the population of Calderdale, West Yorkshire, United Kingdom”, *Annals of Rheumatic Disease*, 1992; 51: 366–71.
2. Bigliani LU, Morrison DS, April EW “The morphology of the acromion and its relationship to rotator cuff tears”. *Orthop Trans*, 1986; 10: 228.
3. Gerber C, Krushell RJ “Isolated rupture of the tendon of the subscapularis muscle, Clinical features in 16 cases”, *J Bone Joint Surg Br*, 1991; 73(3): 389-94.
4. Hand GC, Athanasou NA, Matthews T, Carr AJ “The pathology of frozen shoulder”, *J Bone Joint Surg Br*, 2007; 89: 928-32.
5. Neer CS 2nd “Anterior acromioplasty for the chronic impingement syndrome in the shoulder. 1972”, *J Bone Joint Surg Am*, 2005; 87(6): 1399.
6. Pal B, Anderson J, Dick WC, Griffiths ID “Limitation of joint mobility and shoulder capsulitis in insulin- and non-insulin dependent diabetes mellitus”, *Br J Rheumatol*, 1986; 25: 147-51.
7. Riley D, Lang AE, Blair RD, Birnbaum A, Reid B “Frozen shoulder and other shoulder disturbances in Parkinson’s disease”, *J Neurol Neurosurg Psychiatry*, 1989; 52: 63-6.
8. Sallay PI, Hunker PJ, Lim JK “Frequency of various tear patterns in full-thickness tears of the rotator cuff”, *Arthroscopy*, 2007; 23(10): 1052-9. [Medline].
9. E.M. Shanahan, R. Sladek “Shoulder pain at the workplace”, *Best Practice & Research Clinical Rheumatology*, 2011; 25: 59–68.
10. Uthoff HK, Sano H “Pathology of failure of the rotator cuff tendon”, *Orthop Clin North Am*, 1997; 28(1): 31-41. [Medline].

11. Via AG, De Cupis M, Spoliti M, Oliva F “Clinical and biological aspects of rotator cuff tears”, *Muscles Ligaments Tendons J*, 2013; 3(2): 70-9.
12. Walker-Bone K, Palmer KT, Reading I, Coggon D, Cooper C “Prevalence and Impact of Musculoskeletal Disorders of the Upper Limb in the General Population”, *Arthritis & Rheumatism (Arthritis Care & Research)*, 2004; 51(4): 642-651.
13. Ward AD, Hamarneh G, Ashry R, Schweitzer ME “3D shape analysis of the supraspinatus muscle: a clinical study of the relationship between shape and pathology”, *Acad Radiol*, 2007; 14(10): 1229-41. [Medline].
14. Wong P L K, Tan H C A “A review on frozen shoulder”, *Singapore Med J*, 2010; 51(9): 694.