

## MALIGNANT PARAGANGLIOMA OF NECK: A CASE REPORT AND REVIEW OF LITERATURE

<sup>1</sup>\*Mir Ruquaya, M.B.B.S, DNB, <sup>2</sup>Singh Vikram P., M.B.B.S, M.S

<sup>1,2</sup>Senior Consultant, Indraprastha Apollo Hospitals, New Delhi, India 110019.

Article Received on 03/10/2019

Article Revised on 23/10/2019

Article Accepted on 13/11/2019

### \*Corresponding Author

**Dr. Mir Ruquaya**

Senior Consultant,  
Indraprastha Apollo  
Hospitals, New Delhi, India  
110019.

### ABSTRACT

Malignant paragangliomas are rare tumors of head and neck which are composed of sustentacular and chief cells arranged in Zellballen pattern. Malignant paragangliomas (PGS) are confirmed by presence of cells in lymph nodes or by presence of distant metastasis. PGs of head and neck originate in parasympathetic autonomic nervous system

ganglia and are typically non secretory and benign in nature compared to thoracic and abdominal PGS which arise from sympathetic autonomic nervous system and are usually functional and aggressive in behavior. Because of rarity of tumor there are no clinical trials to guide on the management of these tumors.

**KEYWORDS:** Malignant Paraganglioma, Resection, Radiotherapy, Cranial Nerve involvement.

### CASE SUMMARY

Young lady presented with history of swelling over left side of upper neck for two years. Patient also gave history of headache off and on, associated with vomiting. There was a 3X3cm globular swelling in (L) neck just below angle of mandible, which was firm in consistency. Biopsy of the swelling was attempted elsewhere and was reported as paraganglioma. Ga68 DOTA-NOC PET-CT study showed a mass measuring 24X20X28mm in size along the course of left common carotid artery with evidence of central necrosis. There was another 12X13 mm nodular enhancing lesion in (L) parapharyngeal region on DOTA scan. Preoperative DSA and embolization was done. Left CCA (common carotid

artery) showed a hyper vascular tumor along carotid bifurcation and carotid sheath, encasing the carotid bifurcation. The tumor was primarily supplied by ascending pharyngeal and occipital artery. Embolization of ascending pharyngeal and occipital artery was done with coils (Fig 1, 2).

Intraoperative there was (L) carotid body tumor involving carotid bifurcation with enlarged (L) cervical LNS. There was 1X1 cm lesion near (L) Para pharyngeal space. Excision of (L) carotid bifurcation, external carotid artery was done. After identifying and separating XI, XII and X nerves, Graft reconstruction was done between common carotid artery and left internal carotid. Left Para pharyngeal tumor excision and (L) MND type I was completed. Postoperative recovery was uneventful except for mild headache which was treated with clonidine to which she did respond well. CECT head was done which reported normal with adequate vascularization of both hemispheres of brain. There was no neurological deficit. Patient has completed adjuvant radiotherapy to neck and is symptom free at the end of 12 months.

### **Histopathology Report**

Gross examination showed excised segment of left carotid artery bifurcation with segment of common carotid artery, Internal carotid artery and external carotid artery measuring 3x2x2 cm and weighing 6 gm showing compressed lumen of blood vessels by firm greyish mass. Microscopic examination showed marked desmoplasia with oval to polygonal tumor cells surrounded by eosinophilic cytoplasm. The tumor cells were strongly positive for synaptophysin and S-100 stain. The mib -1 labelling index was 5% (fig 3,4). one out of 28 nodes showed presence of metastatic deposit of tumor with perinodal infiltration.

### **DISCUSSION**

Commonly occurring in the head and neck region, paragangliomas are typically benign, highly vascular neoplasms. Embryologically originating from the extra-adrenal paraganglia of the neural crest, they are typically associated with the vagus, tympanic plexus nerve, the carotid artery, or jugular bulb. Clinically patients with paragangliomas present with diverse signs and symptoms. They may have a family history of paragangliomas and can present with multi-centric tumors regardless of sporadic or familial origin. Family history of paragangliomas, von Hippel-Lindau syndrome, and type 2 multiple endocrine neoplasia should be taken. Sweating, hypertension, tachycardia, and nervousness may be symptoms of secreting tumors. Laboratory studies, including 24- hour urinalysis and serum catecholamine

screening (norepinephrine, epinephrine, and metanephrine), should be ordered for all patients with suspected paragangliomas.<sup>[1, 2, 3]</sup>

Patients with genetic predisposition may have multicentricity in up to 85% of cases. A second carotid body tumor is by far the most common pattern of a synchronous secondary paragangliomas (20% of carotid tumors).<sup>[4, 5]</sup> Approximately 10% of these tumors present an inherited familial form. Presence of multiple paragangliomas, as well as bilateral carotid body tumors, pose a significant and challenging treatment problems for the treating physician. Patients undergoing resection of bilateral carotid body tumors may experience baroreceptor function loss and deficits in the cranial nerves resulting in labile hypertension.<sup>[6]</sup>

A small percentage of extra-adrenal paragangliomas are malignant and do show propensity for involvement of lymph nodes and distant metastasis. No histological criteria exist to diagnose malignancy in primary tumors. There have been attempts to define malignancy based on histologic markers including central necrosis, vascular invasion, and mitosis/nuclear atypical. However, none of these have shown concordance with metastasis or true invasion. Consequently, histologic evidence is considered insufficient to determine malignancy. Similar to the cytoarchitectural findings, local compression and erosion of surrounding structures generally are not accepted as a sign of malignancy.

Site of origin	Incidence of malignancy
SDHB Mutation	30-40%
Orbital and Laryngeal paraganglioma	25%
Vagal paraganglioma	16-19%
Jugulotympanic Paraganglioma	5-6%
Carotid body tumor	3-4%

Reference 1-3, 10 and 11. (SDHB Succinate dehydrogenase complex)

The diagnostic work up includes contrast enhanced computed tomography (CECT) for delineating paragangliomas. The contrast enhances these highly vascular tumors and delineates the relationship of tumor to the internal and external carotid arteries. CT scan also rule out any bony erosion and skull base involvement.

MRI with gadolinium contrast shows intense signal enhancement. On T2-weighted images, the characteristic salt and pepper appearance is pathognomonic and is due to the high-flow vascular voids within the r tumor. Magnetic resonance angiography provide the surgeon with critical information about intracranial circulation and head and neck anatomy. If carotid

artery sacrifice is anticipated, then cerebral angiography with ipsilateral internal carotid balloon occlusion can be obtained at the same time. The venous phase of angiography is equally important particularly in knowing invasion and occlusion of lumen of the jugular bulb, jugular vein, sigmoid sinus, which are characteristic findings of jugulotympanic paragangliomas. Embolization can be done at the time of angiography especially in large paragangliomas. Advantages of embolization include tumor shrinkage, decreased intraoperative bleeding after embolization results in fewer transfusions, making tumor dissection easy and better identification of normal anatomical structures, including the cranial nerves. However, there is a small risk of migration of embolization particles into the cerebral circulation resulting in stroke. Larger paragangliomas usually demonstrate multiple arterial feeding vessels that should be individually addressed through super selective angiography. Surgery is performed within 48 hours of embolization to avoid formation of collaterals.<sup>[7, 8]</sup> The surgical risk to the cranial nerves is site specific and related to tumor size. The risk of injury is more in Vagal nerve paraganglioma followed by jugulotympanic, and carotid body paragangliomas, deficits in the cranial nerve may involve aspiration, deglutition, tongue motion, and phonation. The incidence rate for stroke following surgery for paragangliomas has been reported to be as high as 20% and as low as 2%.

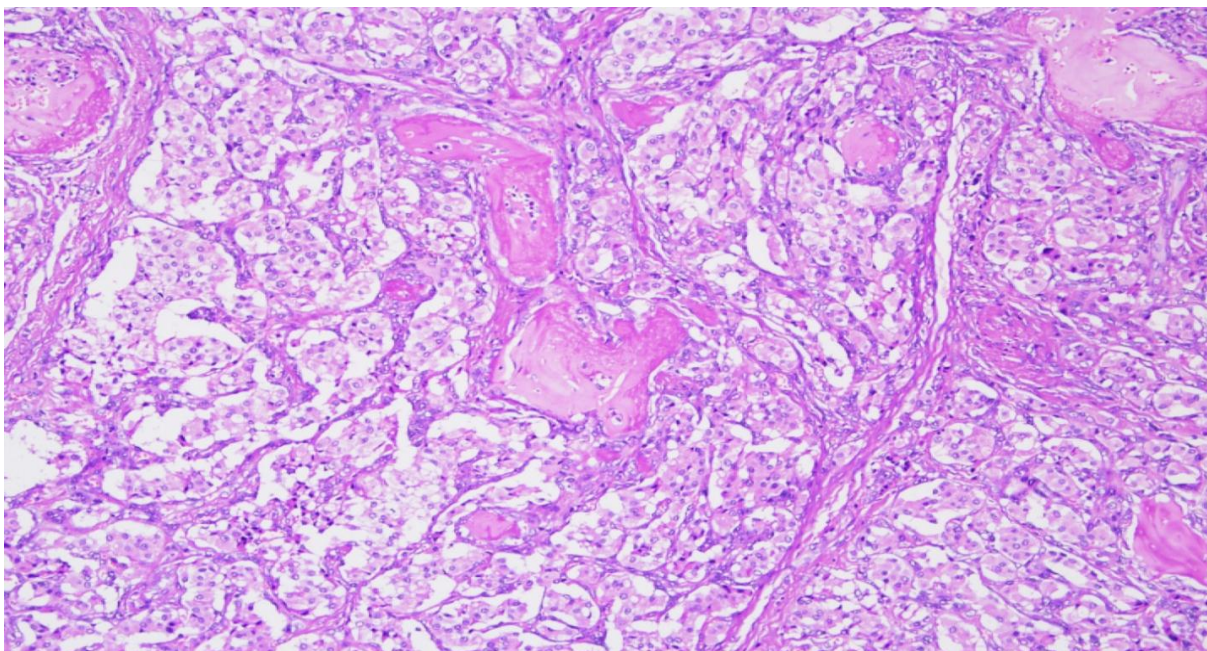
Hypoglossal nerve injury results in paralysis of the ipsilateral tongue. Long-term hypoglossal nerve paralysis results in hemi atrophy of the tongue within a few months.<sup>[17]</sup> Radiotherapy is offered to those patients who are not surgical candidates, synchronous bilateral tumors, patient refusal, advanced age, or associated co-morbidities and in recurrent tumors. Skull-base tumors of jugulotympanic origin and paragangliomas of vagal nerve are primarily treated by Radiotherapy. Radiotherapy may be given with conventional external beam radiotherapy (EBRT), stereotactic radiosurgery, or hypo fractionated stereotactic radiotherapy. All of these approaches have excellent rates of local control and outcomes. Radiotherapy doses of 45 Gy is given in 5 weeks. In a systematic literature review, Suarez et al<sup>[12]</sup> reported on the role of surgery and EBRT in the treatment of carotid body paragangliomas. The mean follow-up times was 80.6 months, disease free interval for surgery (n =2,175) and EBRT arms was 93.8% vs 94.5%, respectively, reduction in tumors size was reported in 25.2% of study patients treated with EBRT. All patients in radiotherapy arm were treated with conventional doses of radiotherapy (40-65 Gy). Iatrogenic cranial neuropathy occurring in cranial nerves X and XII occurred in 22.2% of patients treated with surgery vs 0% in those treating with EBRT (P = .004). The carotid artery was resected in 12.5% because of injury or



tumor encasement, 3% developed permanent stroke, and 1.3% died because of postoperative complications. The rates of iatrogenic cranial neuropathy and vascular complications were 2.3% for shambling class 1, 2 tumors and 35.7% for shamblin class 3 tumors ( $p < .00$ ) with EBRT, a potential increased risk of ischemic stroke of approximately 12% has been observed with long-term follow-up of 15 years.<sup>[13, 14]</sup>

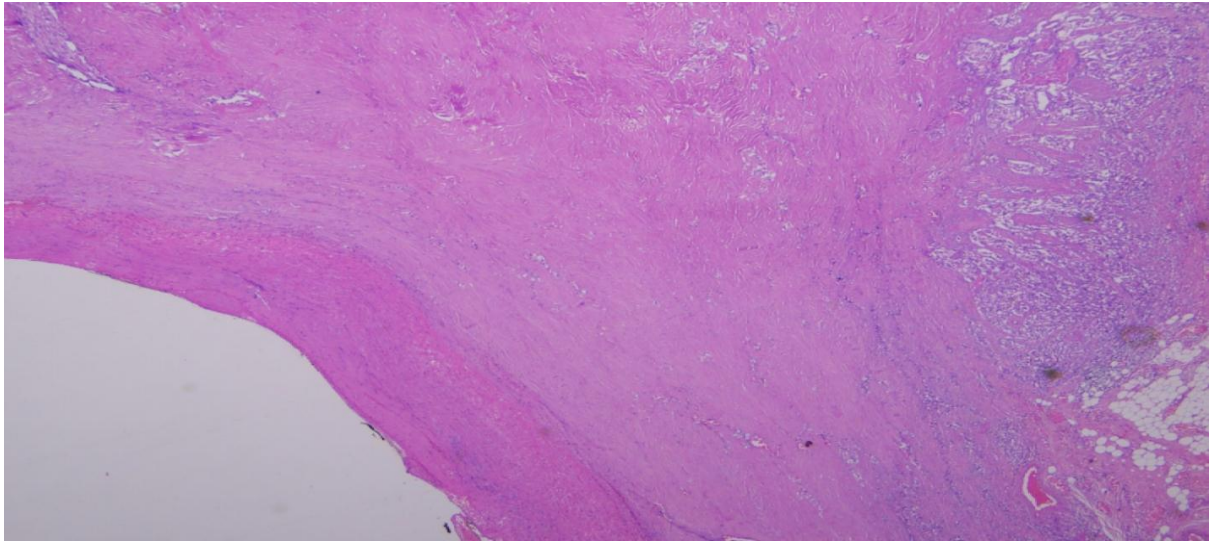
### **Malignant Paranglioma**

Malignant PGs are defined by presence of pathologically confirmed PG cells in lymph node or in distant organs, rather than by the histological features of the primary tumor. Only a small percentage of patients ultimately develop metastatic disease, and malignant PGs are believed to represent only 4% to 15% of all head and neck PG. Loco-regional control is best achieved with primary resection followed by adjuvant radiotherapy. The disease is known to recur up to 20 years. The 5- years survival rates are 50% to 80% for those with nodal disease and up to 11% for those with distant metastasis.<sup>[15,16, 19]</sup> The common site of metastasis is Lung and Liver and is treated with systemic therapy. However, due to the rarity of these lesions, optimal treatment strategies have not been validated to date. metastatic PGs undergoing radiation and chemotherapy.<sup>[16]</sup> The impact of germline mutations in the SHD genes on overall outcomes needs to be studied. Genotype-phenotype correlations have identified distinct mutations that pre-dispose to malignant transformation in paraganglioma. Targeting these mutations can improve outcome in malignant paraganglioma.<sup>[17]</sup>

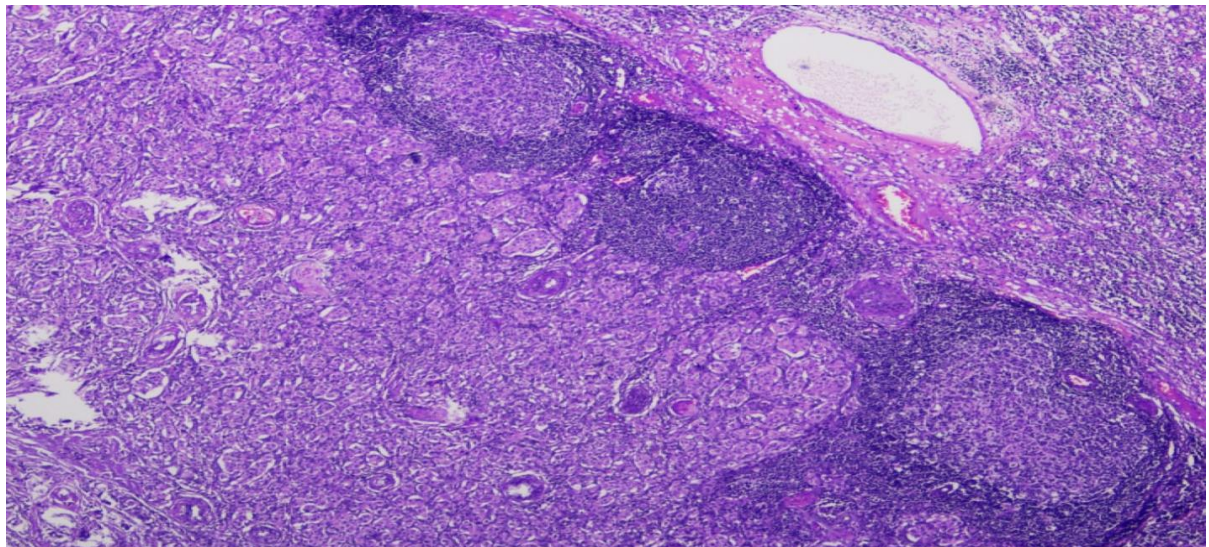


**Fig. 0001: H&E stain, 10x magnification, highlighting the nested pattern of tumor cells.**

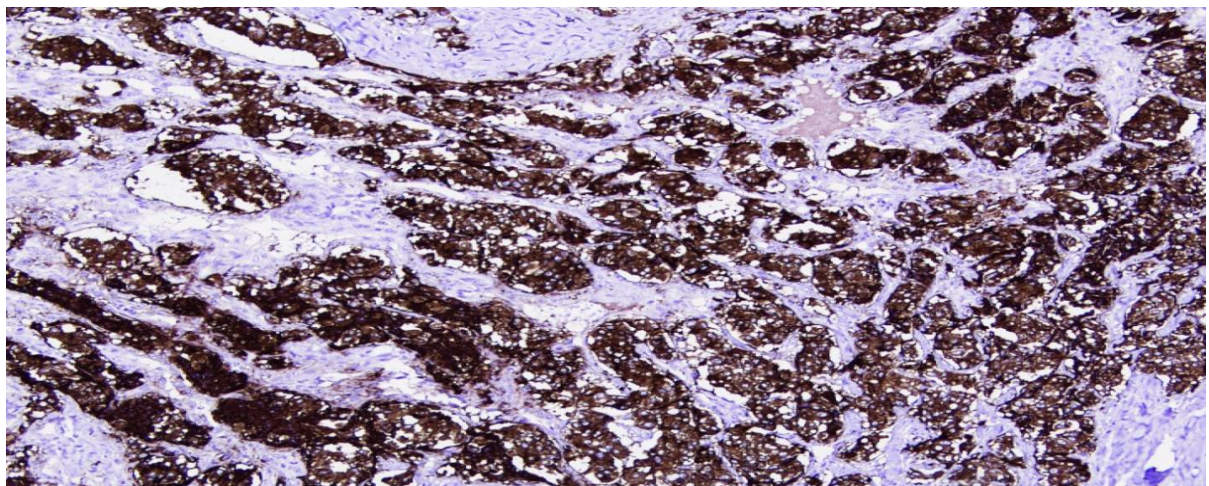




**Fig. 0002: H&E stain, 2x magnification, carotid artery entrapped within the tumor.**

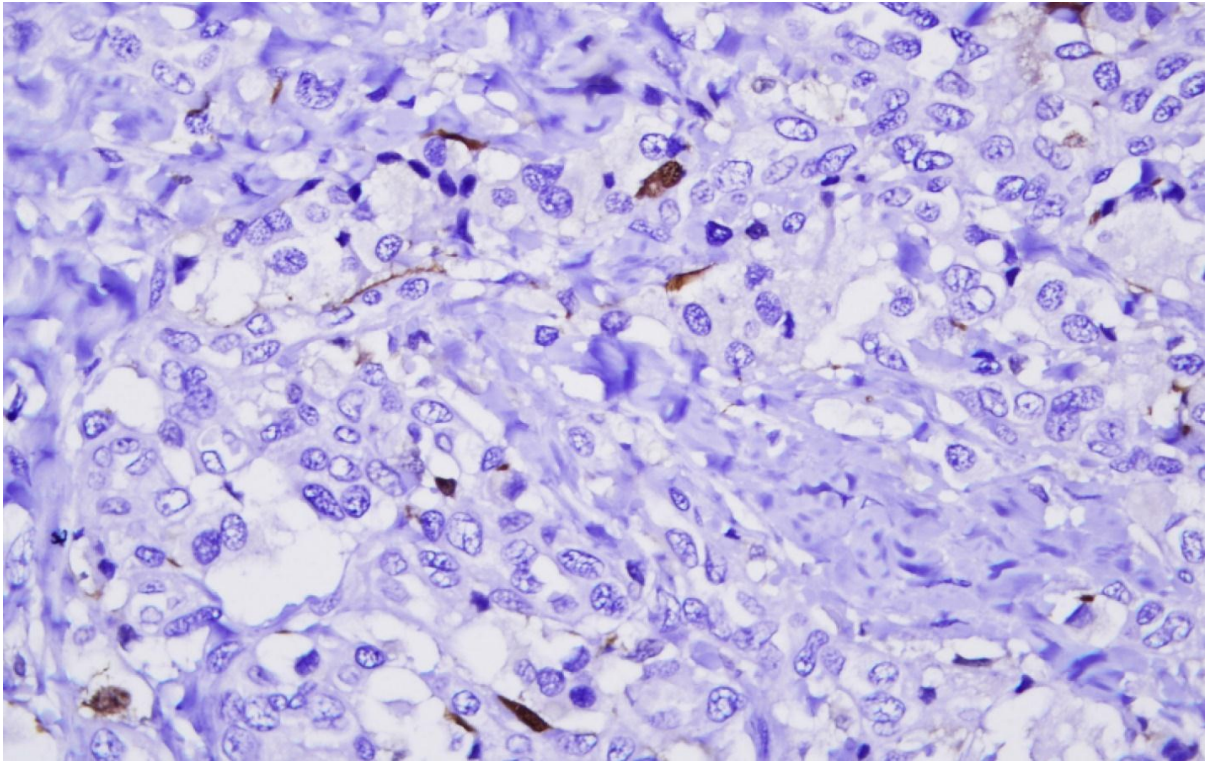


**Fig. 0003: H&E stain, 20x, metastatic deposits in lymph node.**

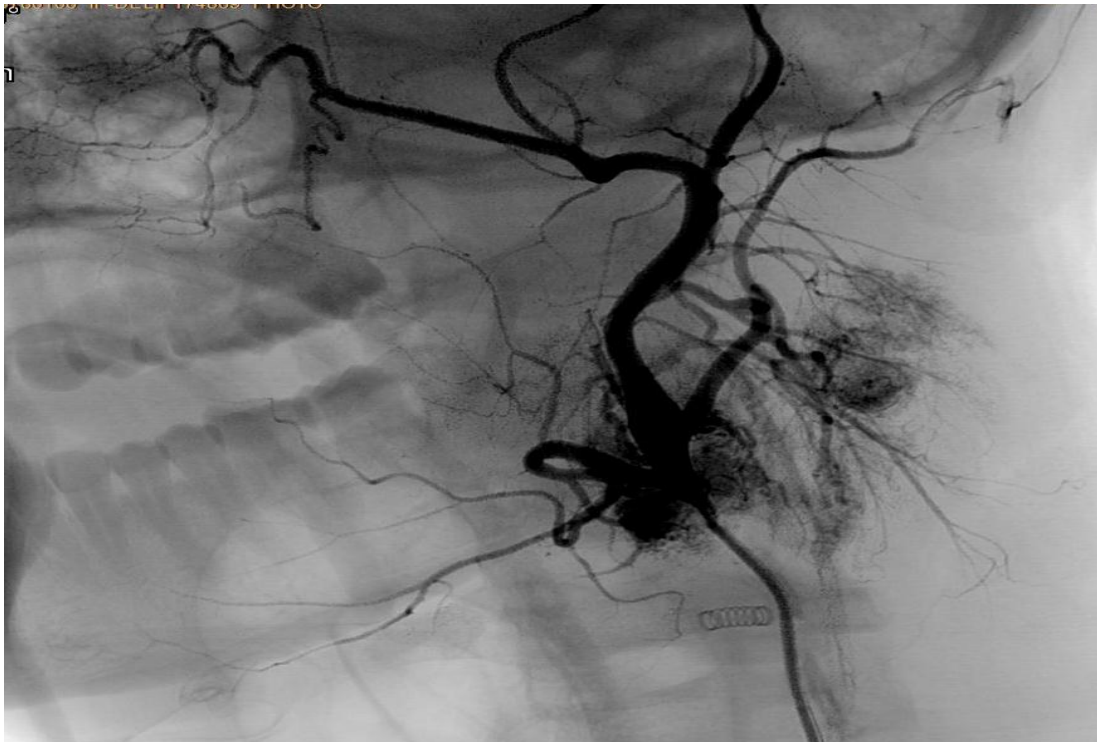


**Fig. 0004: IHC for synaptophysin, 20x, and tumor cells positive.**

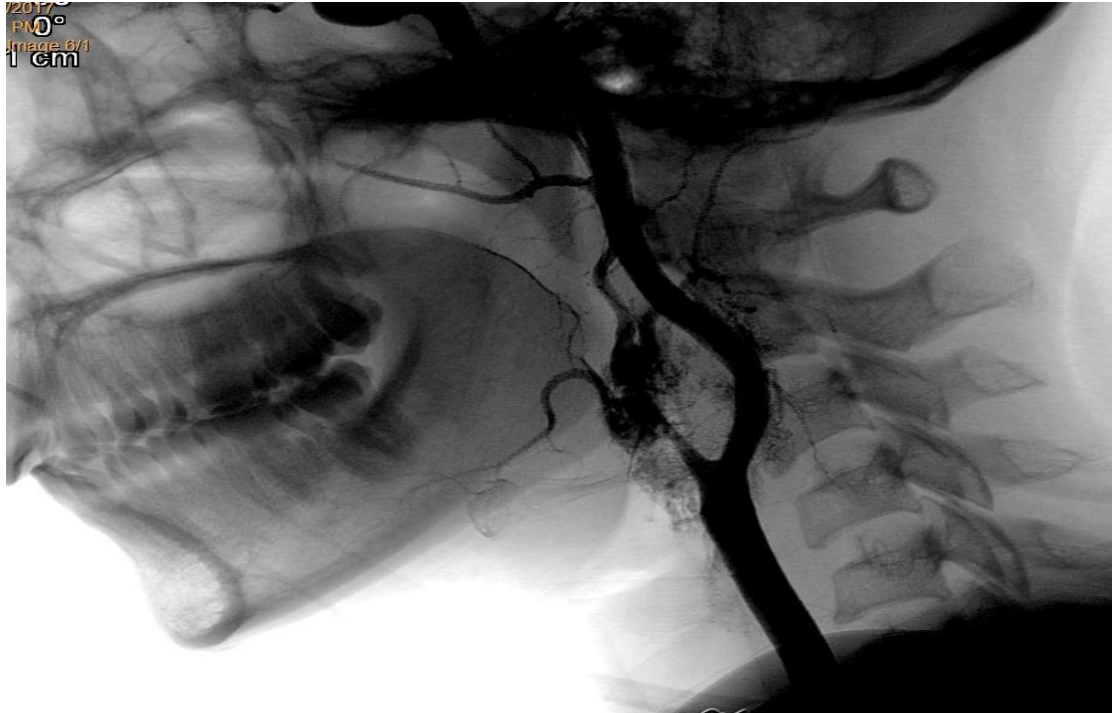



**Fig. 0005: IHC for S-100, occasional sustentacular cells positive.**



**Fig. 0006: Carotid Angiogram showing internal carotid artery narrowing.**



**Fig. 0007: Carotid Angiogram showing internal carotid artery narrowing.**

## CONCLUSION

The management of paragangliomas is challenging due to the complexity of presentations, and the nature of these tumors, rarity of malignant paraganglioma, indolent nature of tumor with the potential to severely deforming tumors.

Observation without treatment is an appropriate initial option in patients who are asymptomatic, particularly among older individuals with comorbidities. In an observational study of 47 tumors followed for 5 years, the researchers found that 38% progressed at an annual growth of 2 mm while 42% were stable and 20% decreased in size.

Treatment decisions should take into account multiple factors such as site of paraganglioma, size, multiplicity, involvement of regional lymph nodes, presence of distant metastasis, age of patient, associated co-morbid conditions and if the tumors is catecholamine secreting or not.

Surgery is preferred for patients with carotid body tumors, especially those whose tumors are less than 5 cm in size and also lack carotid artery encasement.

In cases of bilateral synchronous carotid body tumors, bilateral resection is contraindicated due to baro reflex failure syndrome. Resection of the smaller tumor and radiotherapy to the larger tumor is recommended.



Catecholamine-secreting malignant tumors should be resected followed with adjuvant radiotherapy. Radiotherapy is the preferred modality for the treatment of jugular and vagal paragangliomas with high rates of local control and likely resolution of pre-existing tinnitus and improvement in cranial neuropathy.

First-line radiotherapy should be considered in patients whose tumors are locally advanced, involving base of skull, elderly, patients with multiple comorbidities, cranial nerve neuropathy and encasement of internal carotid artery. Since malignant paragangliomas are relatively slow growing and regionally confined are best treated with surgical resection of tumor and regional lymph nodes is the treatment of choice. Patients with distant metastasis have a poor survival and are treated with chemotherapy.

## REFERENCES

1. Hu K, Persky MS. The multidisciplinary management of paragangliomas of the head and neck, Part 2. *Oncology (Williston Park)*. 2003; 17(8): 1143-1161.
2. Hu K, Persky MS. Multidisciplinary management of paragangliomas of the head and neck, part1. *Oncology (Williston Park)*. 2003; 17(7): 983-993.
3. Persky MS, Hu KS. Paragangliomas of the head and neck. In: Harrison LB, Hong WK, Sessions RB, ed. *Head and Neck Cancer: A Multidisciplinary Approach*. 3<sup>rd</sup> ed. Philadelphia: Lippicott Williams & Wikins; 2009: 655-687.
4. Grufferman S, Gillman MW, Pasternak LR, et al. Familial carotid body tumors: case report and epidemiologic review. *Cancer*. 1980; 46(9): 2116-2122.
5. Netterville JL, Jackson CG, Miller FR, and et al. Vagal paraganglioma: a review of 46 patients treated during a 20-years period. *Arch Otolaryngol Head Neck Surg.*, 1998; 124(10): 1133-1140.
6. Persky MS, Setton A, Niimi Y, et al. Combined endovascular and surgical treatment of head and neck paragangliomas –a team approach *Head Neck.*, 2002; 24(5): 423-431.
7. Jackson CG, McGrew BM, forest JA, et al. Lateral skull base surgery for glomus tumors: long-term control. *OtolNeurotol.*, 2001; 22(3): 377-382.
8. Netterville JL, Civantos FJ. Defect reconstruction following neurotologic skull base surgery. *Laryngoscope* 1993; 103(11 pt 2 suppl 60): 55-63.
9. Brink I, Hoegeris S, Kilsch J, et al. Imaging of pheochromocytoma and paraganglioma. *Fam cancer*. 2005; 4(1): 61-68.

10. Andrews JC, Valavanis A, Fisch U. Management of the internal carotid artery in surgery of the skull base. *Laryngoscope*. 1989; 99(12): 1224-1229.
11. Mature S, Brennan J. Baroreflex failure a rare complication of carotid paraganglioma surgery. *Laryngoscope*. 2006; 116(5): 829-830.
12. Suarez C, Rodrigo JP, Mendenhall WM, et al. Carotid body paragangliomas: a systematic study on management with surgery and radiotherapy. *Eur Arch Otorhinolaryngol.*, 2014; 271(1): 23-34.
13. Smith GL, Smith BD, Buchholz TA, et al. Cerebrovascular disease risk in older head and neck cancer patients after radiotherapy. *J ClinOncol.*, 2008; 26(31): 5119-5125.
14. Scott AS Parr LA, Johnstone PA. Risk of cerebrovascular events after neck and supraclavicular radiotherapy: a systematic review. *RadiotherOncol.*, 2009; 90(2): 163-165.
15. Langerman A, Athavale SM, Rangarajan SV, and et al. Natural history of cervical paragangliomas: outcomes of observation of 43 patients. *Arch Otolaryngol Head Neck Surg.*, 2012; 138(4): 341-345.
16. Sisson JC, Frager MS, Valk TW, et al: Scintigraphic localization of pheochromocytoma. *N Engl J Med.*, 1981; 305: 12-17.
17. JohnH.lee, FrankBarich.LucyHyndsKarnell: National Cancer Base report on malignant paragangliomas of the head and Neck. *Cancer*, 2002; 94(3): 730-737.
18. Fitzgerald PA, Goldsby RE, Huberty JP, et al: Malignant pheochromocytomas and paragangliomas: a phase II study of therapy with high-dose 1311-metaiodobenzylguanidine (1311-MIBG). *Ann N Y AcadSci.*, 2006; 1073: 465-490.
19. Jimenez C, Cote G, and Arnolda, Gagel RF: Review: Should patients with apparently sporadic pheochromocytomas or paragangliomas be screened for hereditary syndromes? *J ClinEndocrinolMetab.*, 2006; 91: 2851-2858.